UPSTATE
Comprehensive
Stroke Center

Endovascular treatment of Cerebral Aneurysms

Grahame C Gould, MD
Assistant Professor
Department of Neurological surgery
Upstate University Medical Center
State University of New York

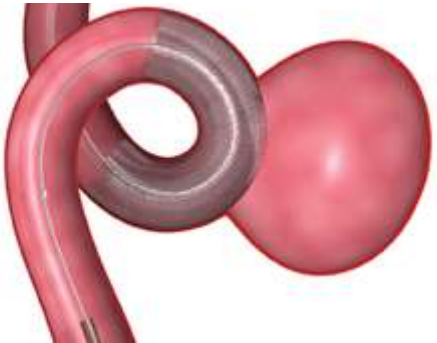

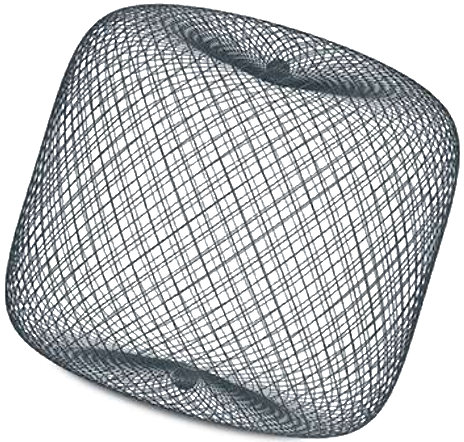

Disclosures

NO CONFLICTS OF INTEREST TO DISCLOSE

Objectives

- Review the natural history and treatment options for intracranial aneurysms
- Discuss current endovascular therapy options for treatment of cerebral aneurysms
- Review relevant published literature
- Evaluate future directions for endovascular treatment of brain aneurysm

What is a cerebral aneurysm?

- What is a cerebral aneurysm?

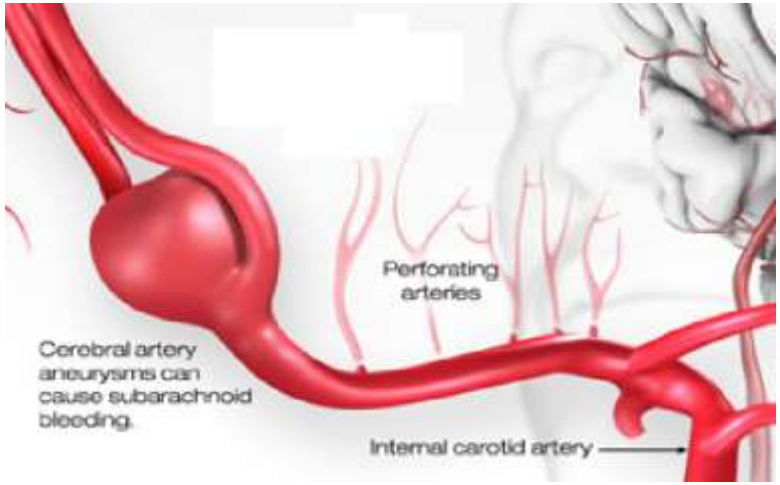

UPSTATE

Comprehensive Stroke Center

Historical Perspective

Historical Perspective

- 1761 Giovanni Batista Morgagni
  - Published first description of an intracranial aneurysm
- 19th Century approach to cerebral aneurysms
  - Parent vessel ligation for surgical treatment
- 1927 Antonio Egas Moniz
  - Cerebral angiography
- 1937 Walter Dandy
  - Clip ligation of aneurysm neck
- 1962 Operating microscope, clips, anesthesia, NICU
- 1971 Godfrey Hounsfield and Allan Cormack
  - First head CT
- 1976 Paul Lauterbur, Peter Mansfield, and Raymond Damadian
  - First MR scan
- 1990 Guido Guglielmi
  - Detachable coils

Natural History

- *Ruptured intracranial aneurysms*
  - 50% mortality with additional morbidity for survivors
  - Urgent treatment for high risk of re-rupture for patients that have a meaningful prognosis
- *Unruptured intracranial aneurysms*[1]

Unruptured intracranial aneurysms: natural history, clinical outcome, and risks of surgical and endovascular treatment	<7 mm		7–12 mm	13–24 mm	≥25 mm
	Group 1*	Group 2†			
Cavernous carotid artery (n=210)	0%	0%	0%	3·0%	6·4%
Anterior cerebral artery, anterior communicating artery, middle cerebral artery, or internal carotid artery (excluding cavernous segment) (n=1037)	0%	1·5%	2·6%	14·5%	40%
Posterior circulation‡ or posterior communicating artery (n=445)	2·5%	3·4%	14·5%	18·4%	50%

*No history of subarachnoid haemorrhage. †History of subarachnoid haemorrhage from a separate aneurysm. ‡Any vertebrobasilar or posterior cerebral artery segment aneurysm. Reproduced from Wiebers and colleagues,[36] by permission of Elsevier.

Table 2: 5-year cumulative aneurysm rupture rates according to size and location of unruptured aneurysm

  - Additional Risk Factors: Cigarette smoking, family history, hypertension, aneurysm morphology

Unruptured Intracranial Aneurysm: Treatment Options

Clip vs Coil?

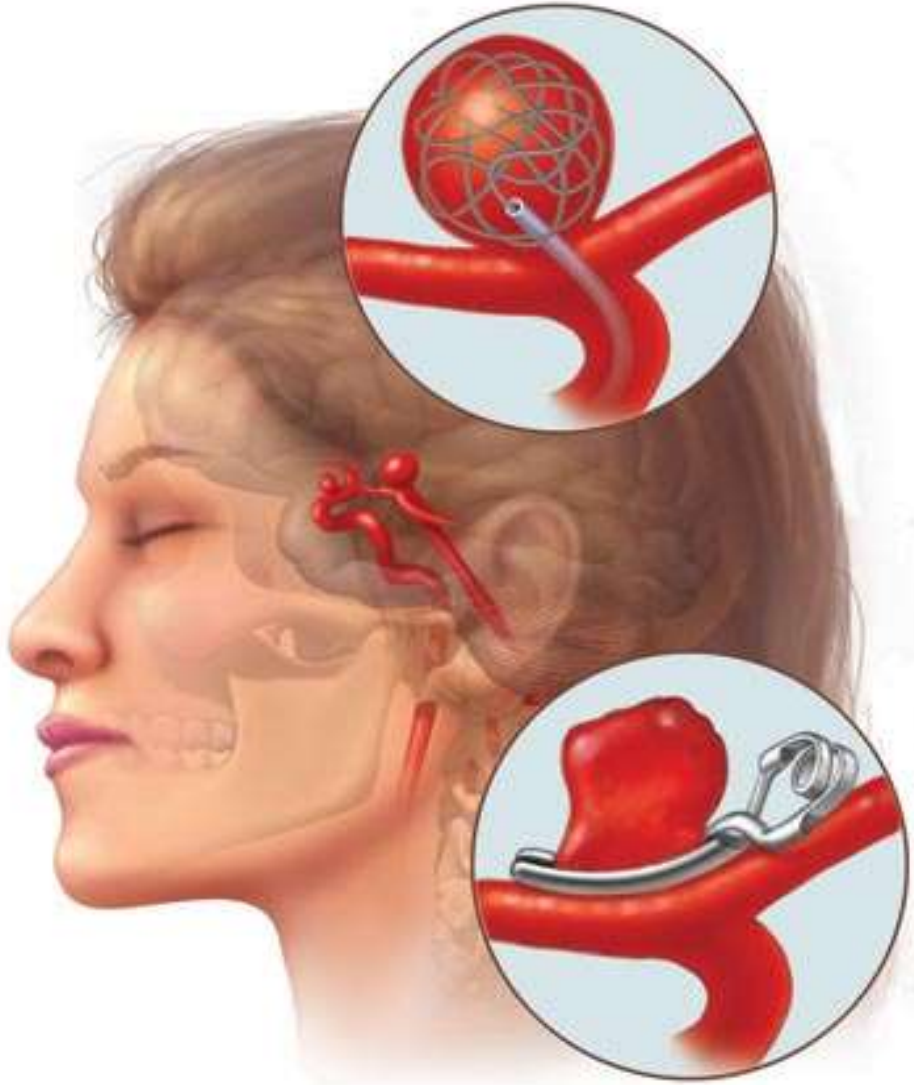

Unruptured Intracranial Aneurysm: Treatment Options

Observation vs Treatment



Unruptured Cerebral Aneurysm: Treatment Options

Microsurgical clip ligation

- M/M ranging from < 1% to 50% from small anterior circ to giant posterior circ aneurysms (overall 2.6% mortality, 10.9% morbidity)[1]
- Increased risk for age > 50, aneurysm > 12 mm, and posterior circulation[2]
- Physical manipulation of neural and vascular structures, post-operative recovery time, surgical site, cosmetic, and cognitive complaints

1. Raaymakers TW, et al. Mortality and morbidity of surgery for unruptured intracranial aneurysms: a meta-analysis. *Stroke*. 1998;29:1531-1538.
2. Wiebers DO, et al. Unruptured intracranial aneurysms: natural history, clinical outcome, and risks of surgical and endovascular treatment. *Lancet*. 2003;362:103-110.

Unruptured Cerebral Aneurysm: Treatment Options

Endosaccular coil embolization:

- ATENA[1] (739 aneurysms < 15 mm)
  - 5.4% morbidity and mortality
  - 4.3% aborted procedure
  - 59% complete occlusion, 21.7% neck remnant, 19.3% aneurysm remnant
- Recurrence 16.5-26.4%, more associated with wide neck[2,3]
- Difficult to treat complex shapes, tortuous anatomy
- Failure to address mass effect

1. Pierot L, et al. Immediate clinical outcome of patients harboring unruptured intracranial aneurysms treated by endovascular approach: Results of the ATENA study. *Stroke*. 2008;39:2497-2504.
2. Gallas S, et al. Feasibility, procedural morbidity and mortality, and long-term follow-up of endovascular treatment of 321 unruptured aneurysms. *Am J Neurorad*. 2008;29:63-68.
3. Choi DS, et al. Clinical and angiographic long-term follow-up of completely coiled intracranial aneurysms using endovascular technique. *J Neurosurg*. 2010;112(3):575-581.

Ruptured Cerebral Aneurysm



Clip vs Coil?

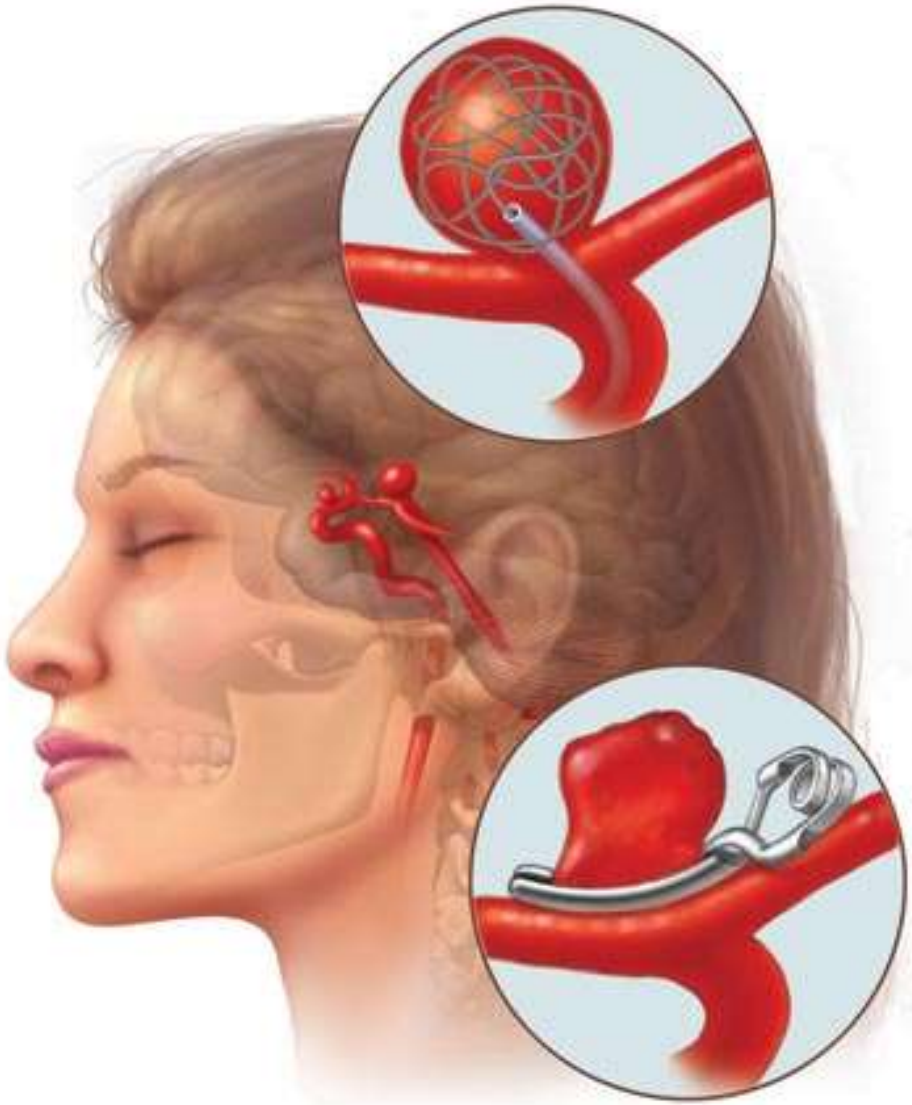

UPSTATE
Comprehensive Stroke Center

International subarachnoid aneurysm trial (ISAT) of neurosurgical clipping versus endovascular coiling in 2143 patients with ruptured intracranial aneurysms: a randomised comparison of effects on survival, dependency, seizures, rebleeding, subgroups, and aneurysm occlusion

*Andrew J Molyneux, Richard S C Kerr, Ly-Mee Yu, Mike Clarke, Mary Sneade, Julia A Yarnold, Peter Sandercock, for the International Subarachnoid Aneurysm Trial (ISAT) Collaborative Group**

	2 month outcome		1 year outcome	
	Endovascular n=1065	Neurosurgery n=1063	Endovascular n=1063	Neurosurgery n=1055
Modified Rankin Scale				
0 No symptoms	203 (19·1%)	144 (13·6%)	260 (24·5%)	187 (17·7%)
1 Minor symptoms	310 (29·1%)	273 (25·7%)	301 (28·3%)	292 (27·7%)
2 Some restriction in lifestyle	274 (25·7%)	254 (23·8%)	252 (23·7%)	250 (23·7%)
(0-2 inclusive)	787 (73·9%)	671 (63·1%)	813 (76·5%)	729 (69·1%)
3 Significant restriction in lifestyle	107 (10·1%)	189 (17·8%)	107 (10·1%)	141 (13·4%)
4 Partly dependent	34 (3·2%)	46 (4·3%)	30 (2·8%)	42 (4·0%)
5 Fully dependent	62 (5·8%)	73 (6·9%)	28 (2·6%)	38 (3·6%)
6 Dead	75 (7·0%)	84 (7·9%)	85 (8·0%)	105 (9·9%)
(3-6 inclusive)	278 (26·1%)	392 (36·9%)	250 (23·5%)	326 (30·9%)

Table 2: Clinical outcome at 2 months and 1 year

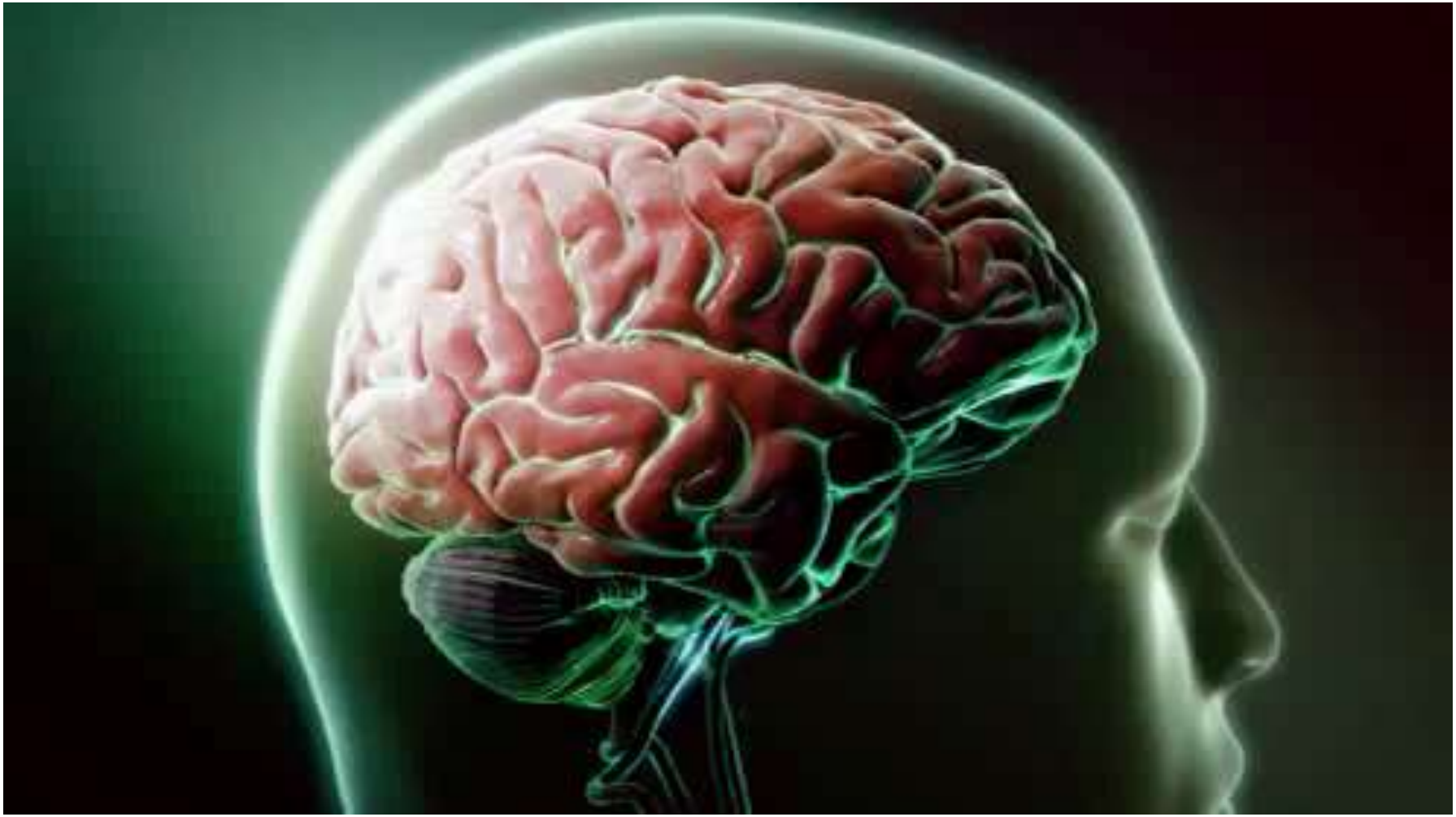

Ruptured Acomm Aneurysm

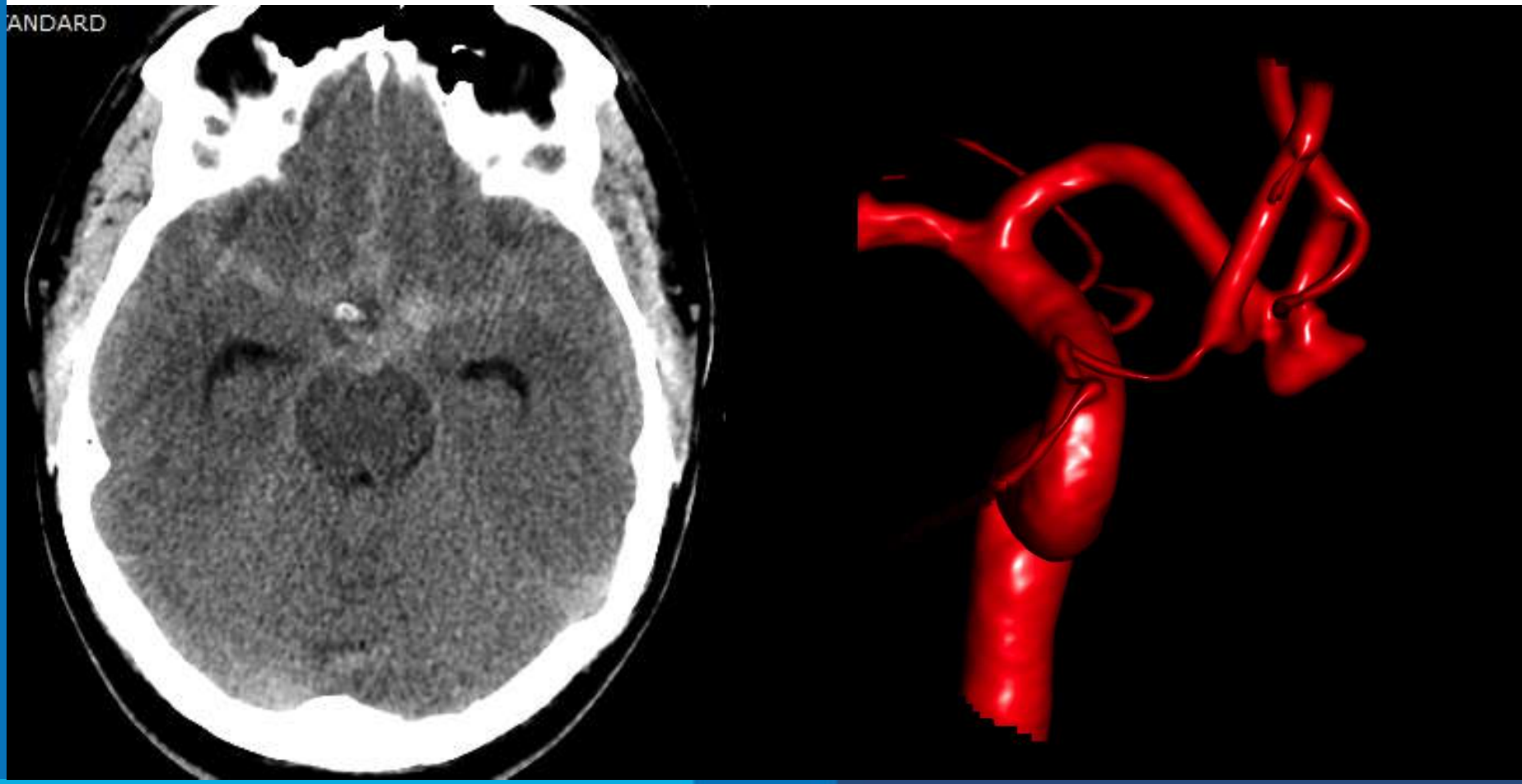

Coil embolization

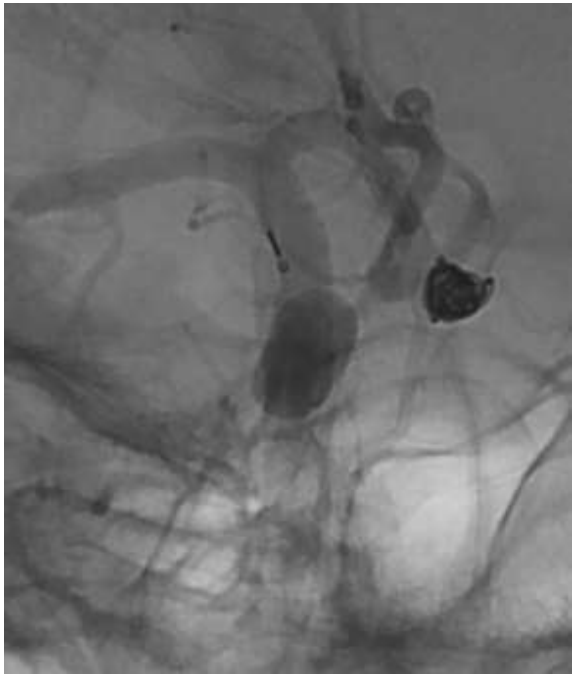

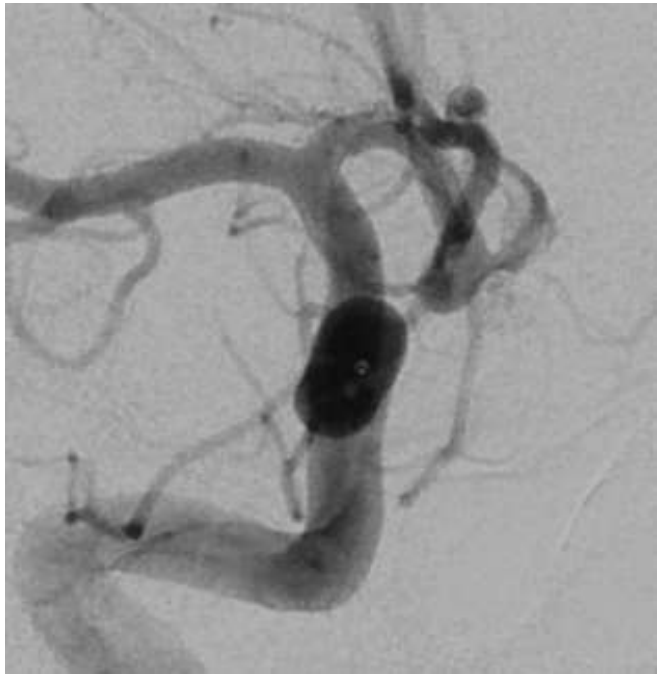

Adjuncts to Endosaccular Coiling

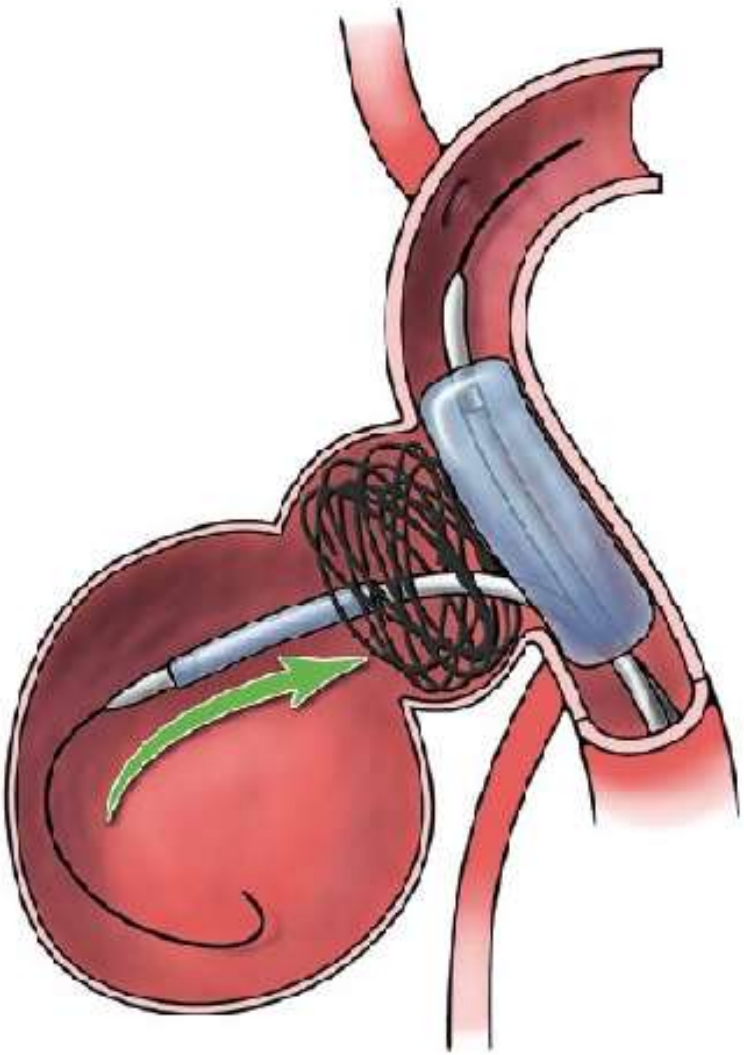

SAH, Basilar tip aneurysm

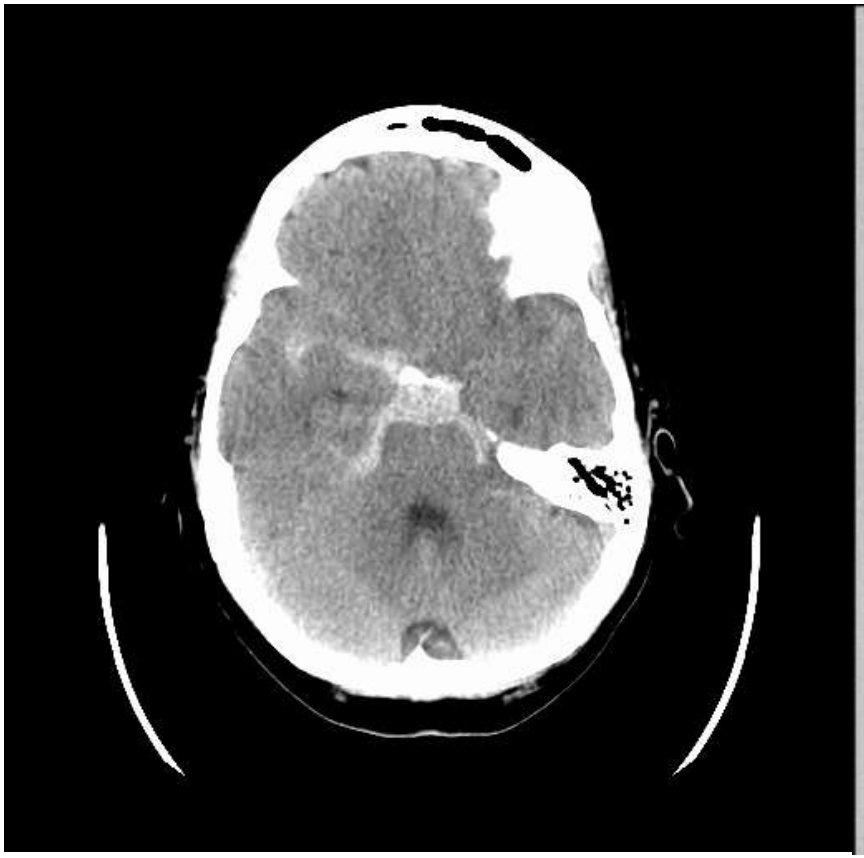

Balloon assisted coil embolization

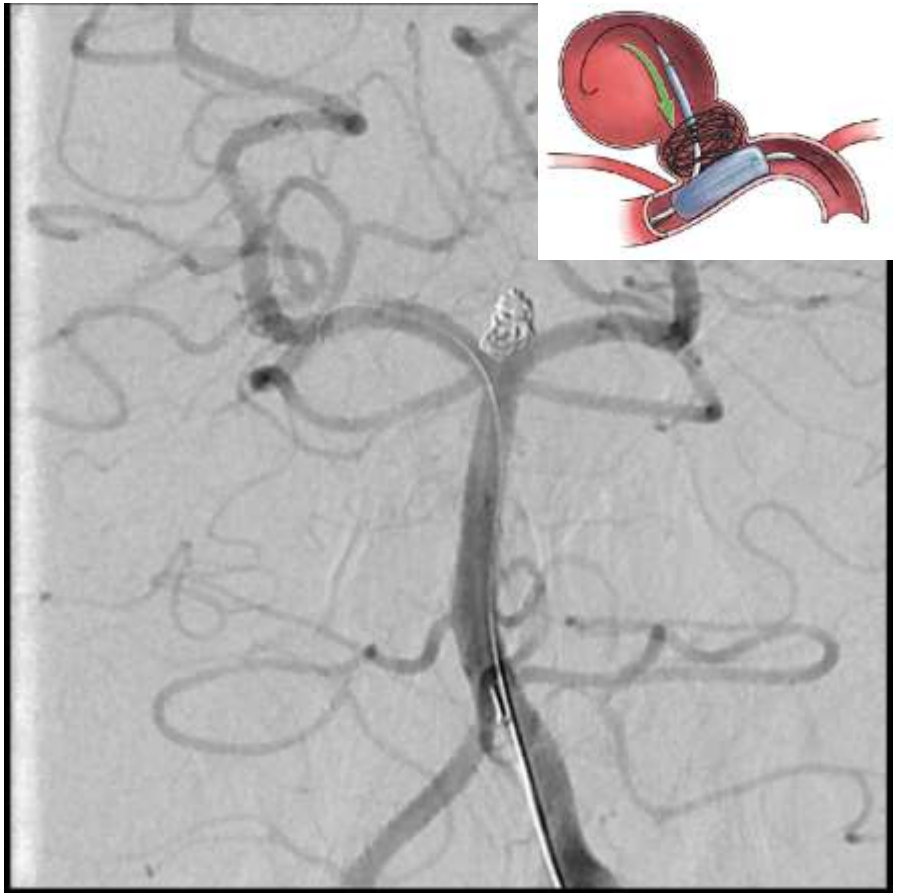

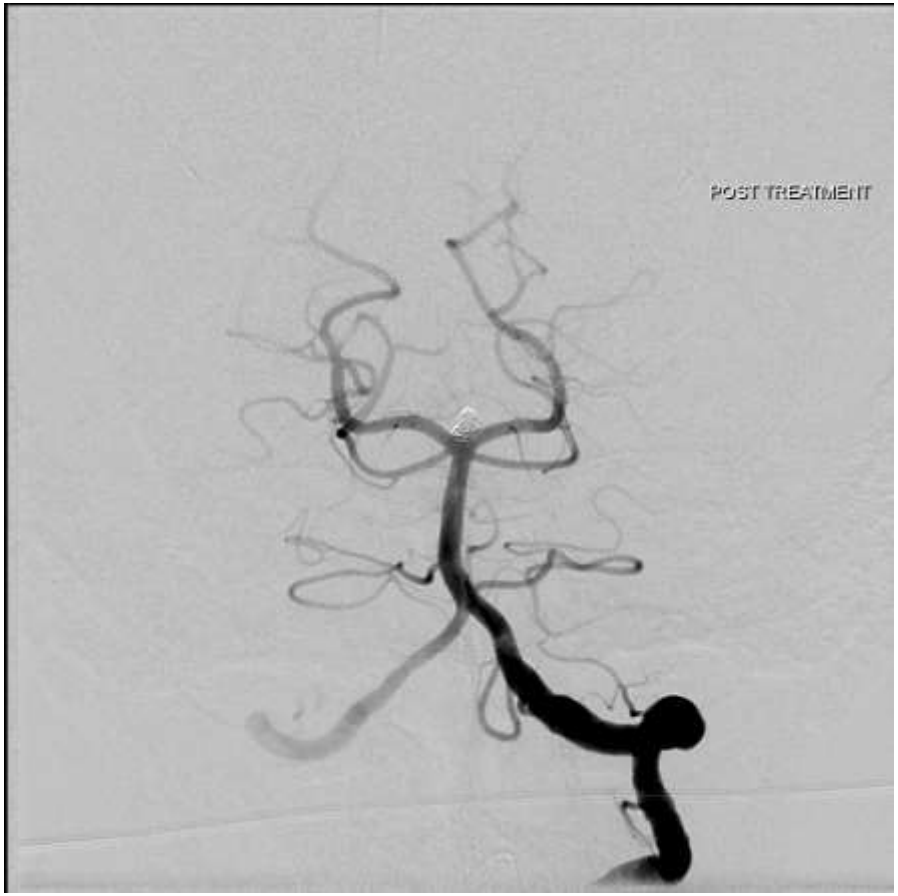

Adjuncts to Endosaccular Coiling

Unruptured Intracranial Aneurysm?

Adjuncts to Endosaccular Coiling

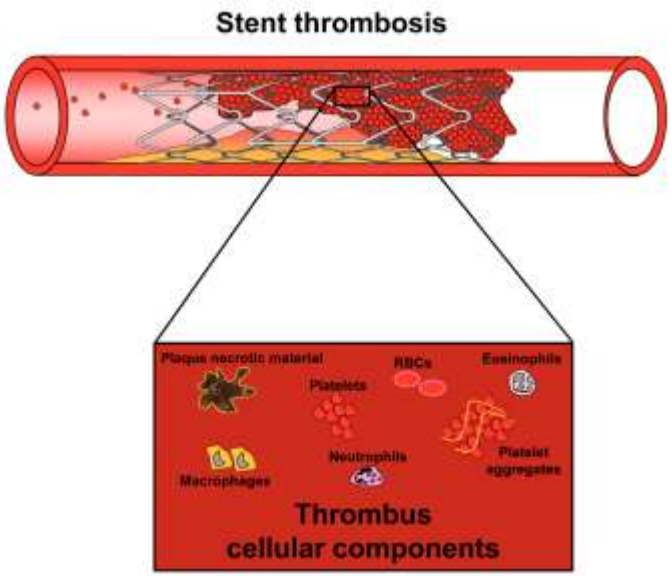

vs

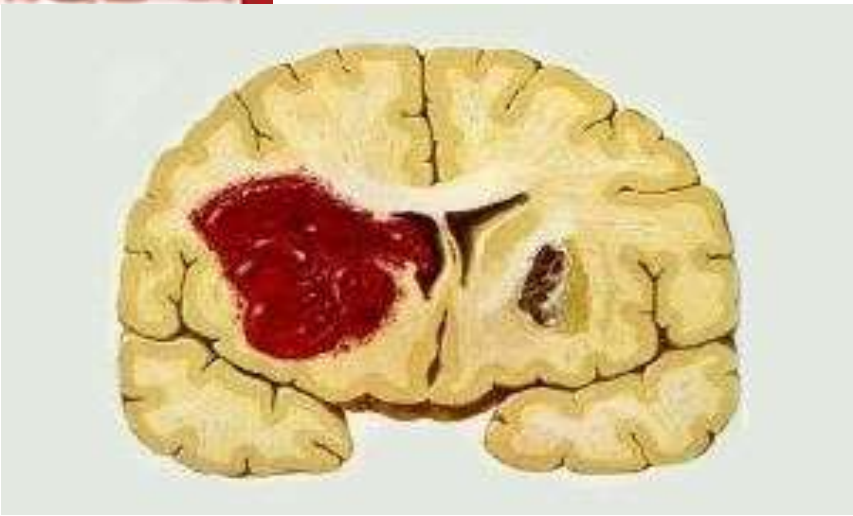

Broad neck Acomm aneurysm

Stent assisted coil embolization

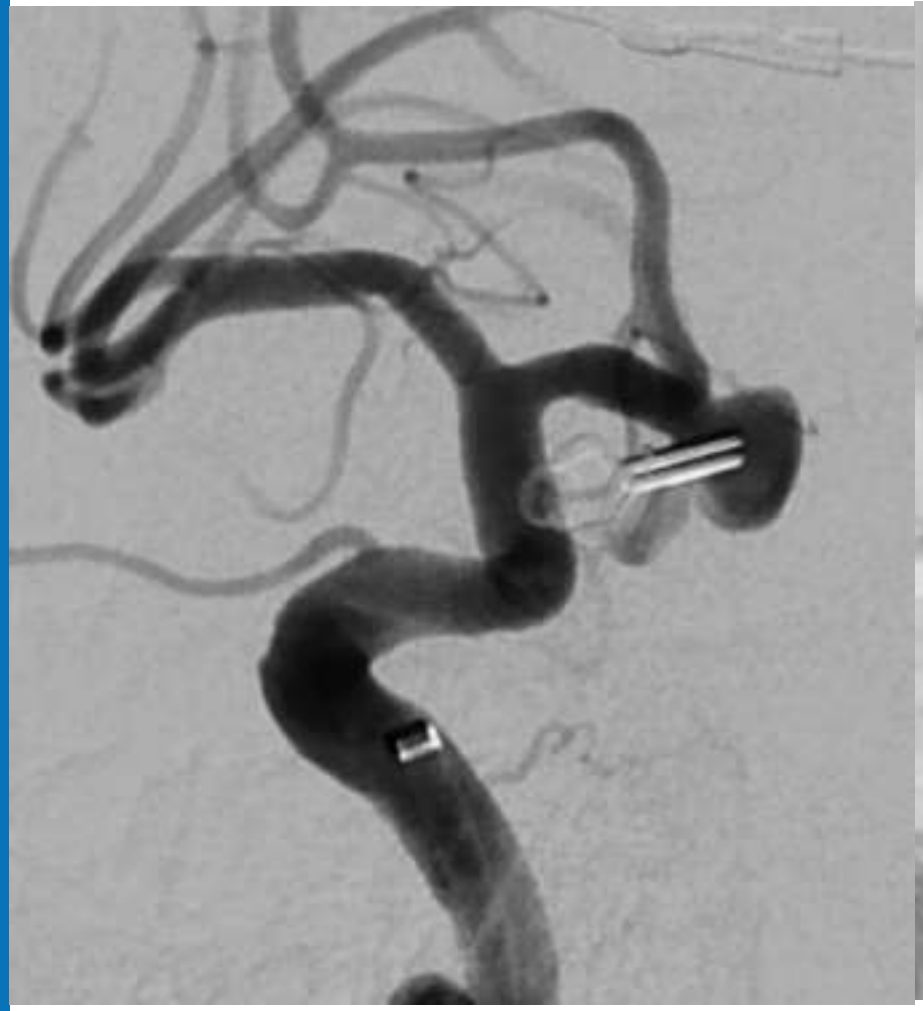

Post stent-coil

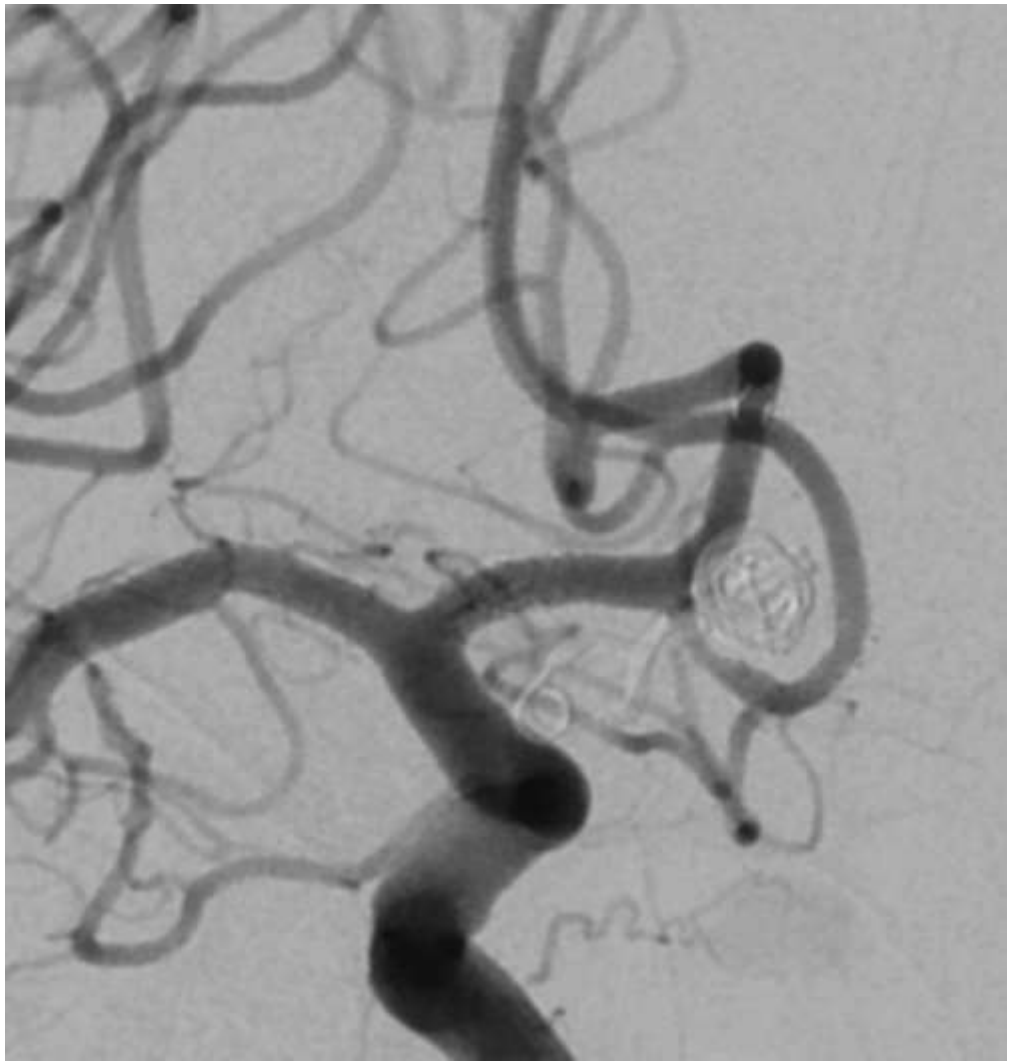

Covered Stent for LAD perforation

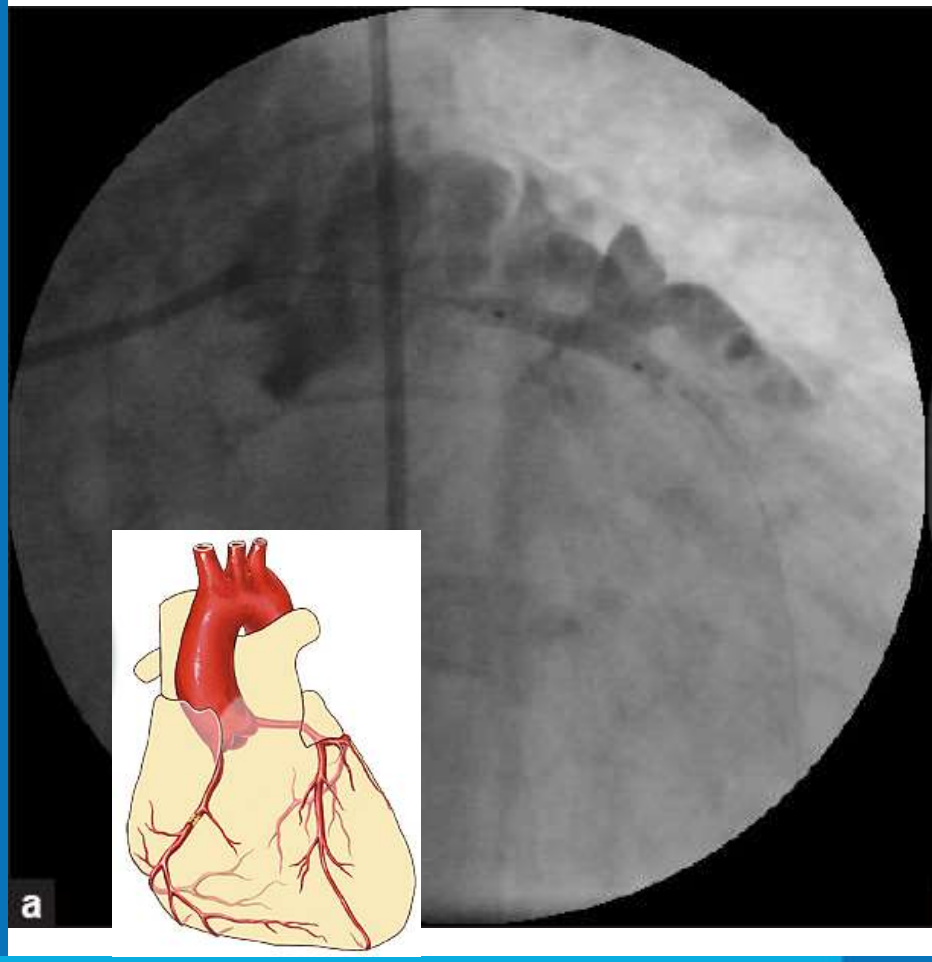

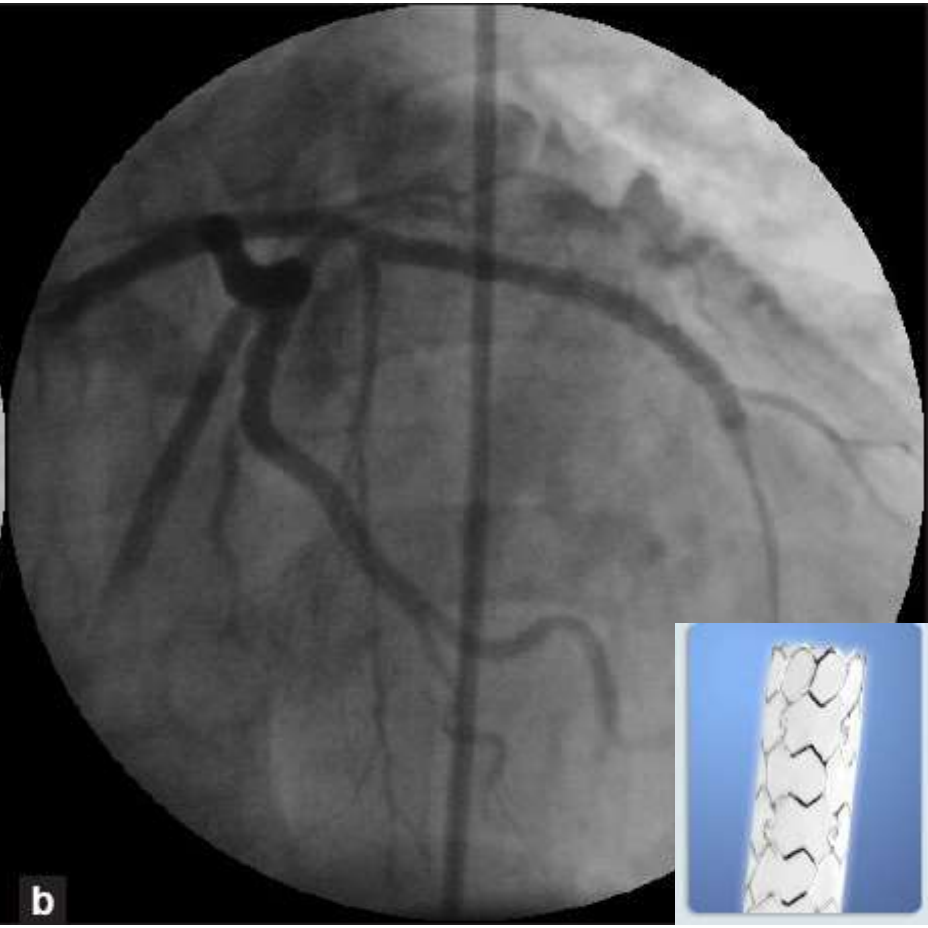

Critical perforator arteries, Tortuosity

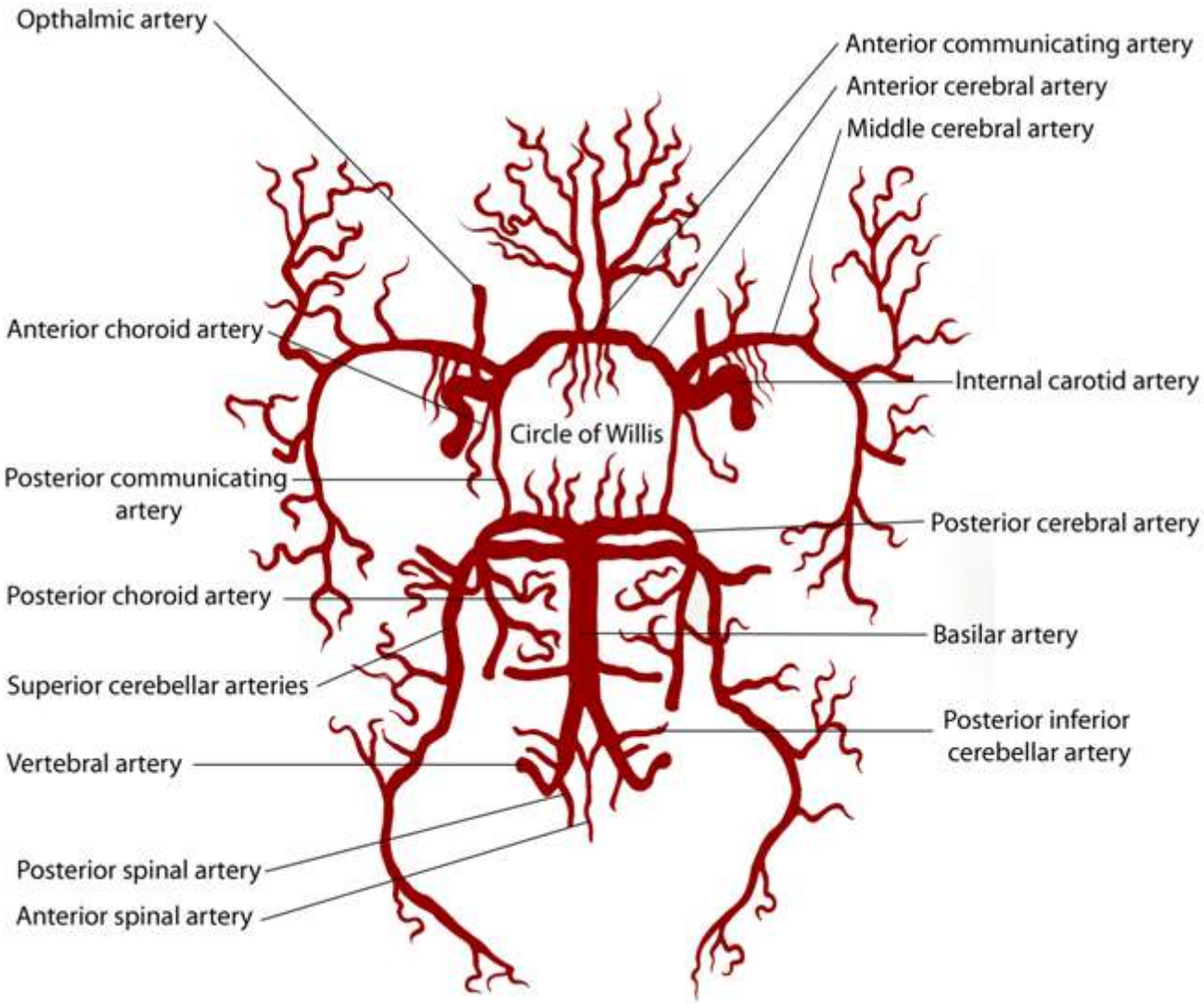

Porosity: ratio of open area/total stent area
Pore density: the number of pores/area
Metal Coverage: ratio of covered area/total stent area



50%



50%

Porosity: ratio of open area/total stent area
Pore density: the number of pores/area
Metal Coverage: ratio of covered area/total stent area

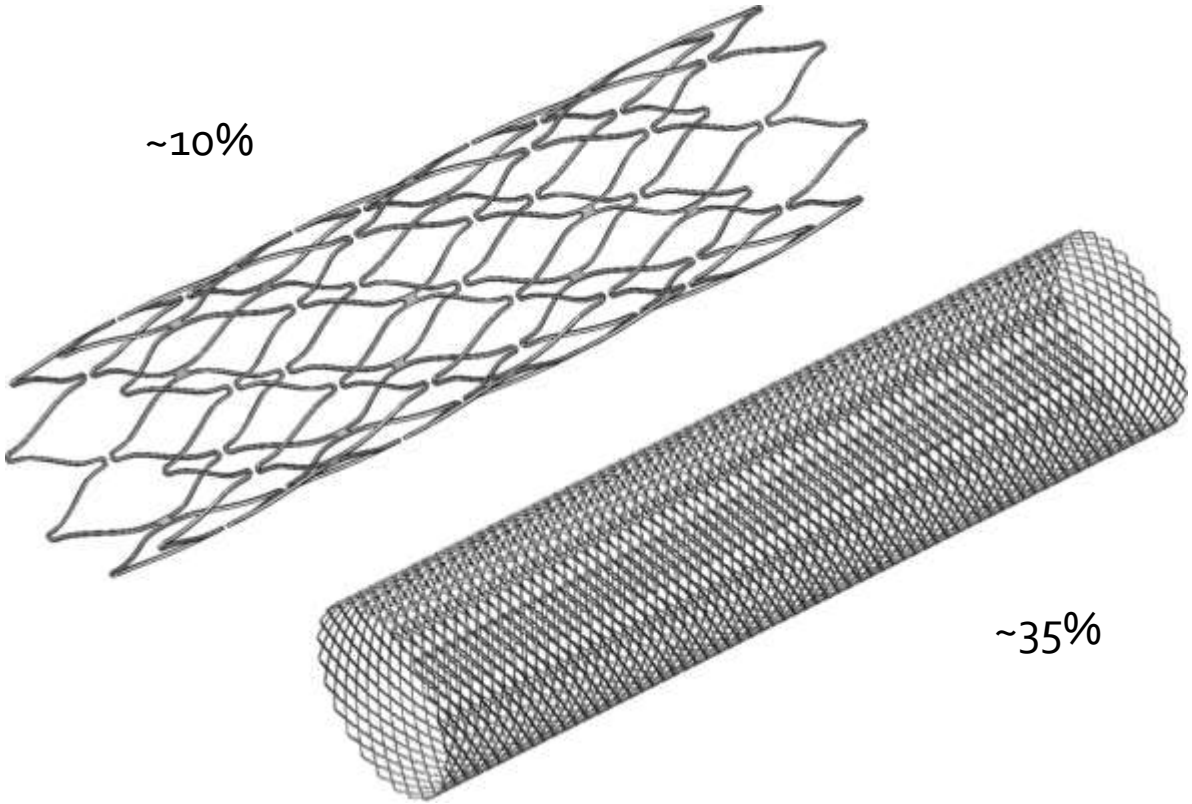

Modeling Flow Diversion (PIV)

Particle imaging velocimetry evaluation of intracranial stents in sidewall aneurysm: hemodynamic transition related to the stent design. Bouillot P, Brina O, Ouared R, Lovblad KO, Farhat M, Pereira VM. PLoS One. 2014 Dec 3;9(12

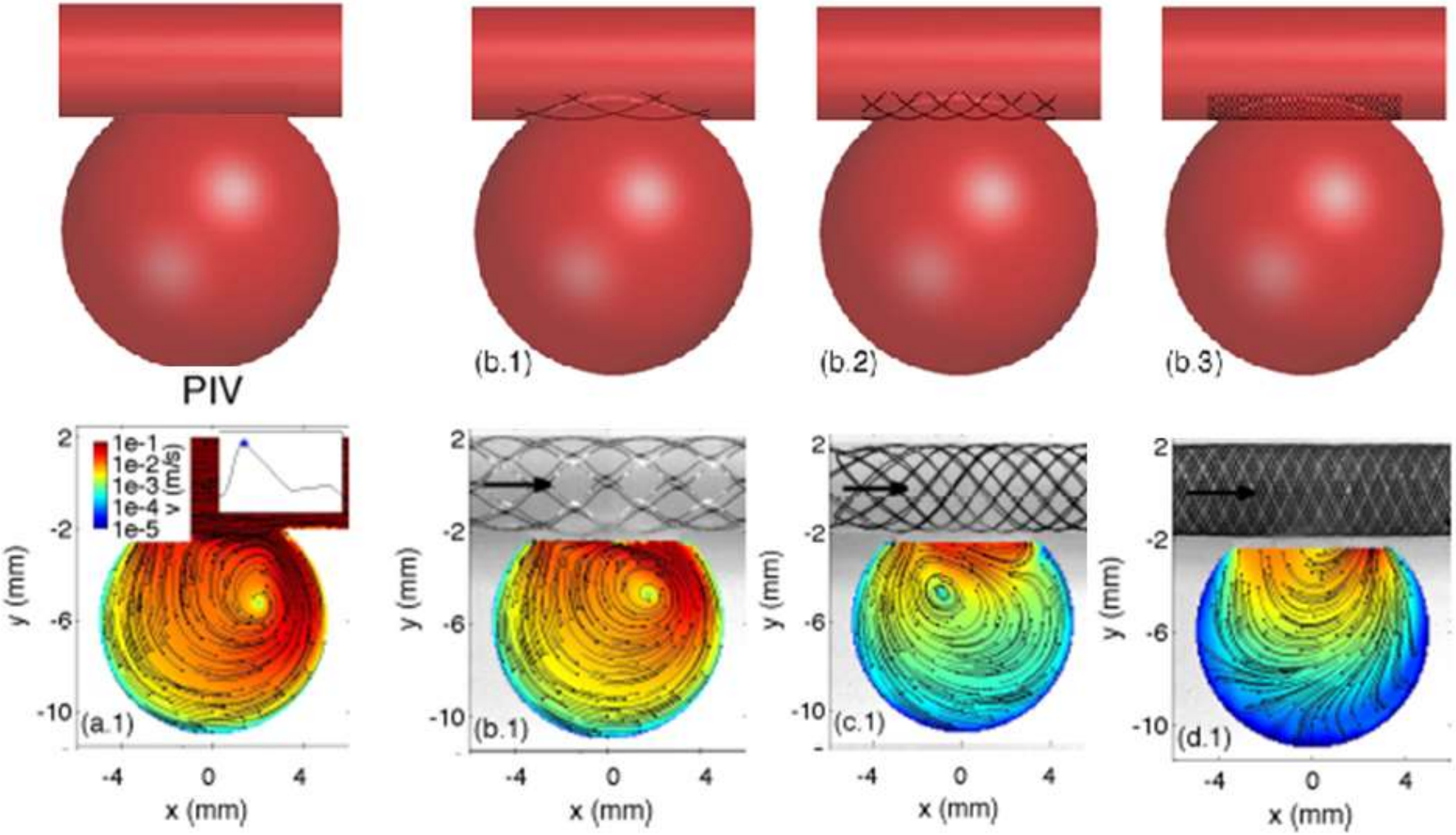

Rabbit aneurysm model

D'Urso - Stroke 2011
Kallmes - Stroke 2007

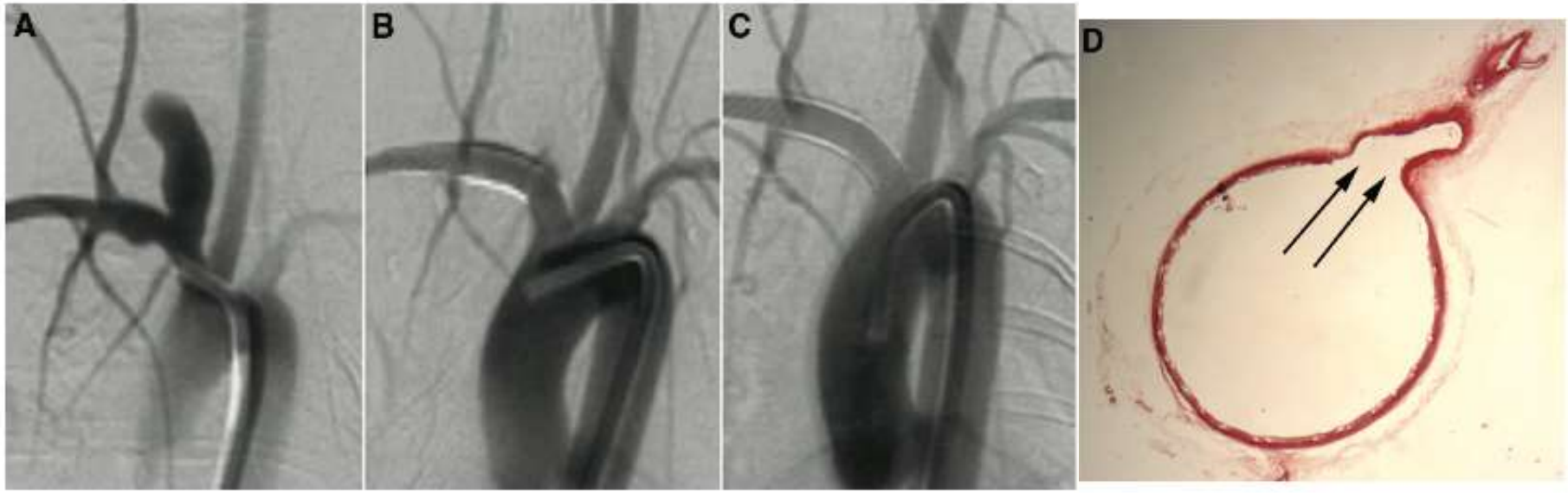



Flow diversion: Theoretical Mechanism of Action

- Creates stasis in the aneurysm
- Stasis favors thrombosis
- Creates a scaffold for endothelium growth
- *Pressure gradient/outflow maintains patency of branch arteries*

Current Flow Diverters

Silk® (CE)



Pipeline Flex® (FDA)

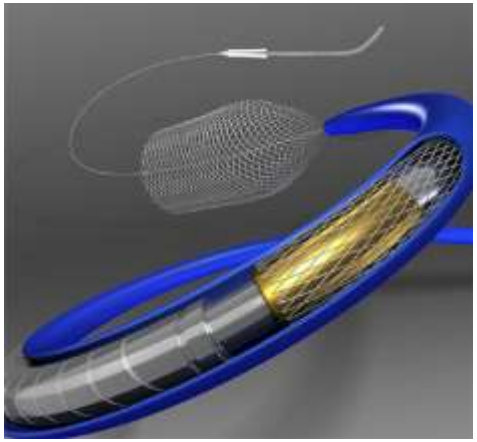

FRED® (CE/IDE)

Surpass® (CE/IDE)

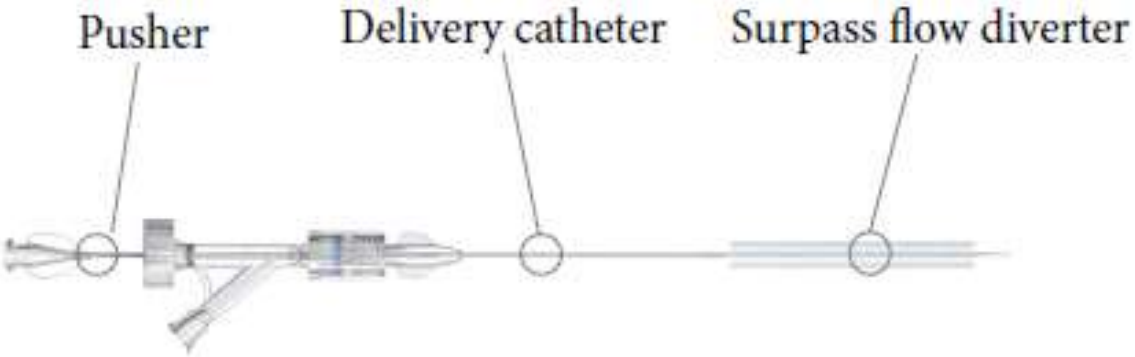

Pipeline Flex Video

FDA Indications for Use

Indication

The Pipeline® Flex Embolization Device is indicated for the endovascular treatment of adults (22 years of age or older) with ***large or giant*** wide-necked intracranial aneurysms (IAs) in the ***internal carotid artery from the petrous to the superior hypophyseal segments***.

Contraindications

Patients with active bacterial infection.
Patients in whom dual anti platelet therapy (aspirin and Clopidogrel/Plavix®) is contraindicated.
Patients who have not received anti platelet agents prior to the procedure.
Patients in whom a pre-existing stent is in place in the parent artery at the target aneurysm location.

Pipeline: Medical Evidence

Pipeline® Embolization Device Clinical Results				
	PUFs Trial[1]	PITA Trial[2]	Buenos Aires Experience[3]	Budapest Experience[4]
Number of Aneurysms	106	31	63	19
Number of Patients	104	31	53	28
Mean Aneurysm Size	18.2 mm	11.5mm	11.1mm	16mm
Occlusion Rate* - 6 Months	82%	93%	93%	94%
Occlusion Rate* - 1 Year	86%	Not Reported	94%	Not Reported
Recurrence Rate	0%	0%	0%	0%
Major Stroke or Neurologic Death	5.6%	6.5%	0.0%	5.3%

References:

1. Chestnut Medical FDA Panel Presentation
2. Nelson, et al. The Pipeline Embolization Device for the Intracranial Treatment of Aneurysm Trial (PITA). American Journal of Neuroradiology, 32:34-40, Dec 2010.
3. Lylyk P, Miranda C, Ceratto R, et al. Curative Endovascular Reconstruction of Cerebral Aneurysms with the Pipeline Embolization Device: The Buenos Aires Experience.Neurosurgery 64:632-643, 2009
4. Szikora I, Berentei Z, Kulcsar Z, et al. Treatment of Intracranial Aneurysms by Functional Reconstruction of the Parent Artery: The Budapest Experience with the Pipeline Embolization Device. American Journal of Neuroradiology 31:1139-1147, June-July 2010

Complications of flow diversion

Complications of flow diversion: Intraparenchymal Hemorrhage

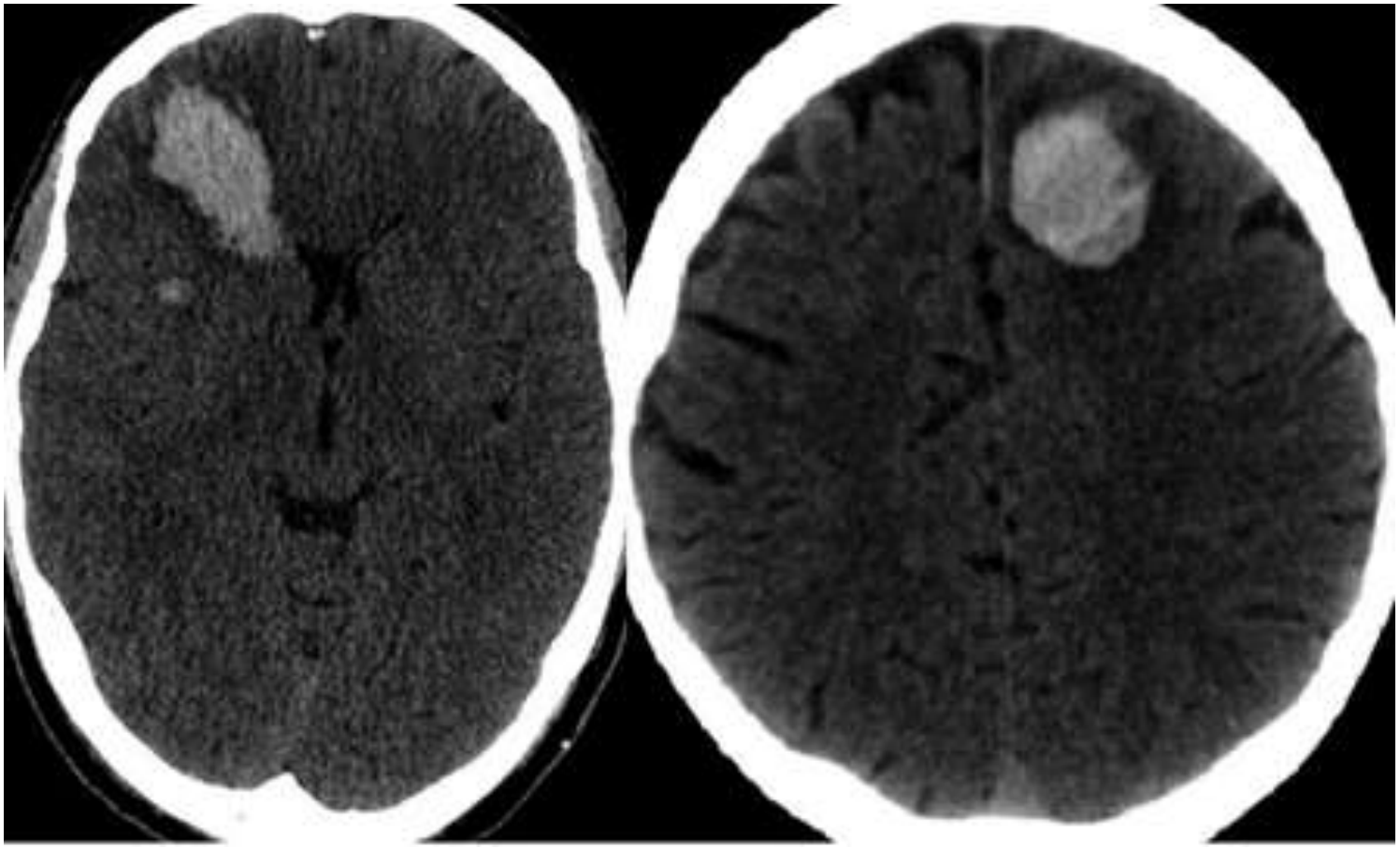

Complications of flow diversion: Late Aneurysm Rupture

Complications of flow diversion: Device stenosis and ischemia

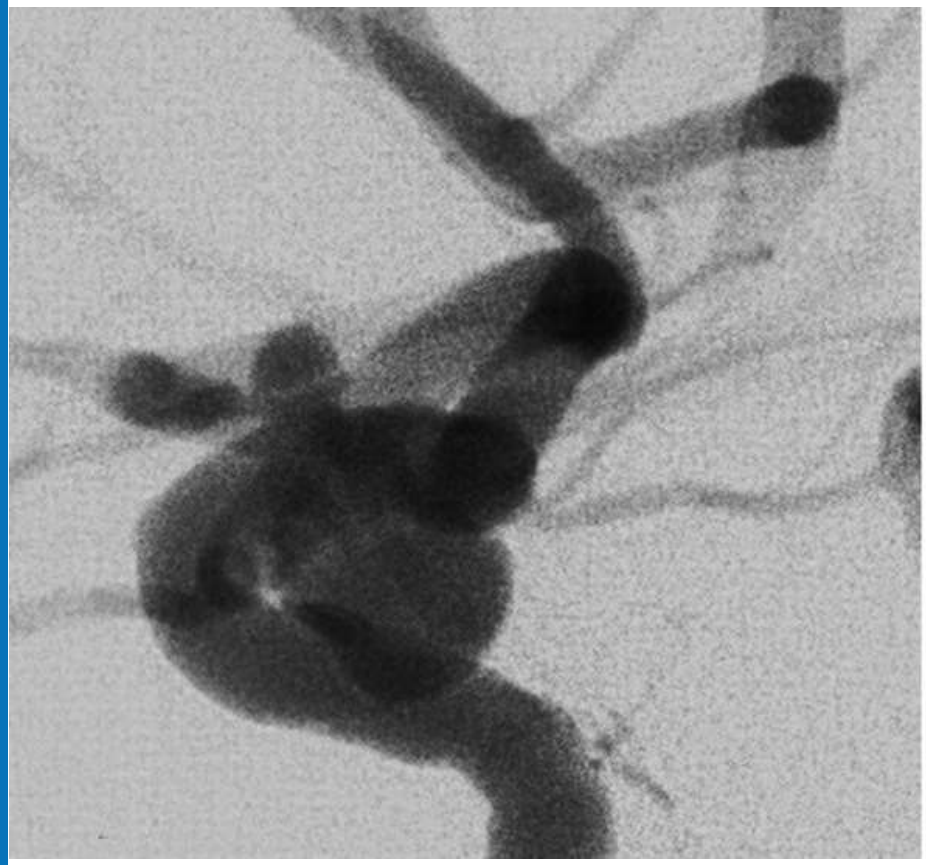

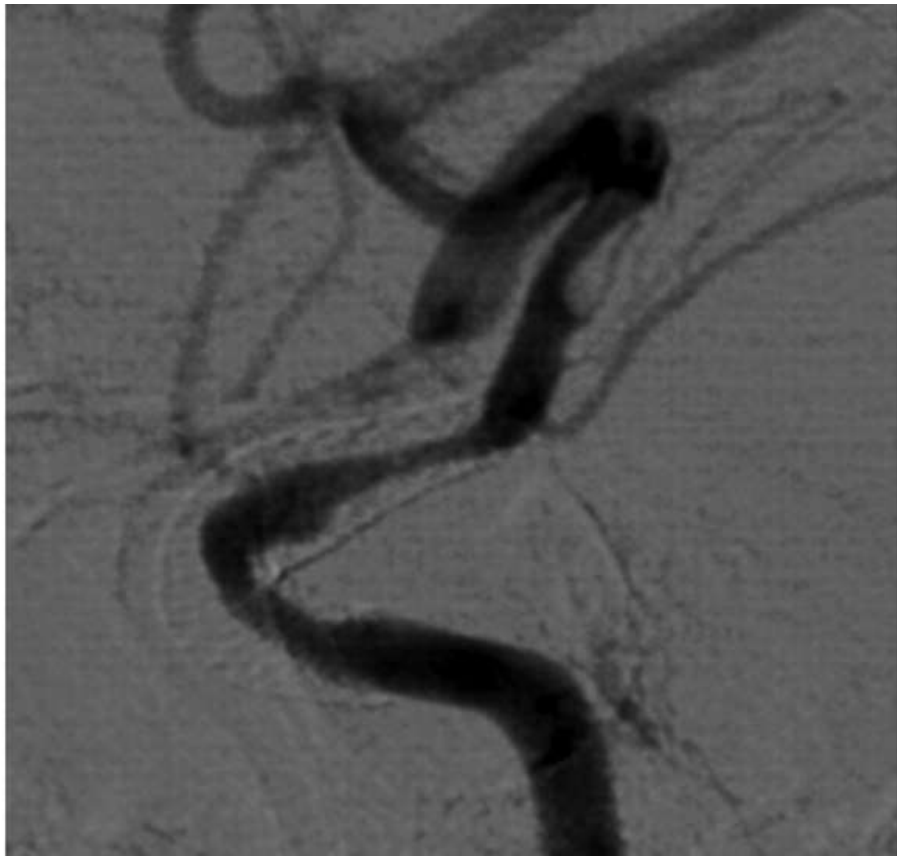

IntrePED (Retrospective Study)

- n = 793 patients, 906 aneurysms, 76 ruptured
- **Neurologic morbidity = 7.4%**
  - Posterior circ = 16.4%, Anterior circ = 4.8%
  - Giant = 25.8%, large = 8.8%, small = 5.4%
- **Neurologic mortality = 3.8%**
  - Posterior circ = 10.9%, Anterior circ = 1.4%
  - Giant = 9.6%, large = 5.0%, small = 1.8%

Kallmes DF, et al. International retrospective study of the pipeline embolization device: a multicenter aneurysm treatment study. *AJNR Am J Neuroradiol.* 2015 Jan;36(1):108-15.

IntrePED (Retrospective Study)

- **Spontaneous rupture = 0.6%** (4/5 within 30 d)
  - Giant = 4.5%, large = 0.6%, small = 0.0%
- **Intraparenchymal hemorrhage = 2.4%**
  - No subgroup difference, 79% within 30 days
- **Ischemic stroke = 4.7%**
  - Posterior circ = 7.3%, anterior circ = 2.7%
  - Giant = 14.5%, large = 5.0%, small = 2.8%
- In-stent stenosis = 0.3%
- Cranial neuropathy = 0.3%

Kallmes DF, et al. International retrospective study of the pipeline embolization device: a multicenter aneurysm treatment study. *AJNR Am J Neuroradiol.* 2015 Jan;36(1):108-15.

Learning Curve

Pipeline versus "traditional" endovascular means

Stroke
Journal of the American Heart Association

Comparison of Flow Diversion and Coiling in Large Unruptured Intracranial Saccular Aneurysms

Nohra Chalouhi, MD; Stavropoula Tjoumakaris, MD; Robert M. Starke, MD; L. Fernando Gonzalez, MD; Ciro Randazzo, MD; David Hasan, MD; Jeffrey F. McMahon, BS; Saurabh Singhal, MD; Lea A. Moukarzel, BA; Aaron S. Dumont, MD; Robert Rosenwasser, MD; Pascal Jabbour, MD

- Complete occlusion **in 86% of PED** vs. **41% of coiled** aneurysms (p<0.001)
- Retreatment in **in 2.8% of PED** vs. **37% of coiled** aneurysms (p<0.001)
- Favorable outcome (mRS, 0–2) in 92% of PED group vs. 94% of the coil group (*P=0.8)*

65 y/o F intractable HA

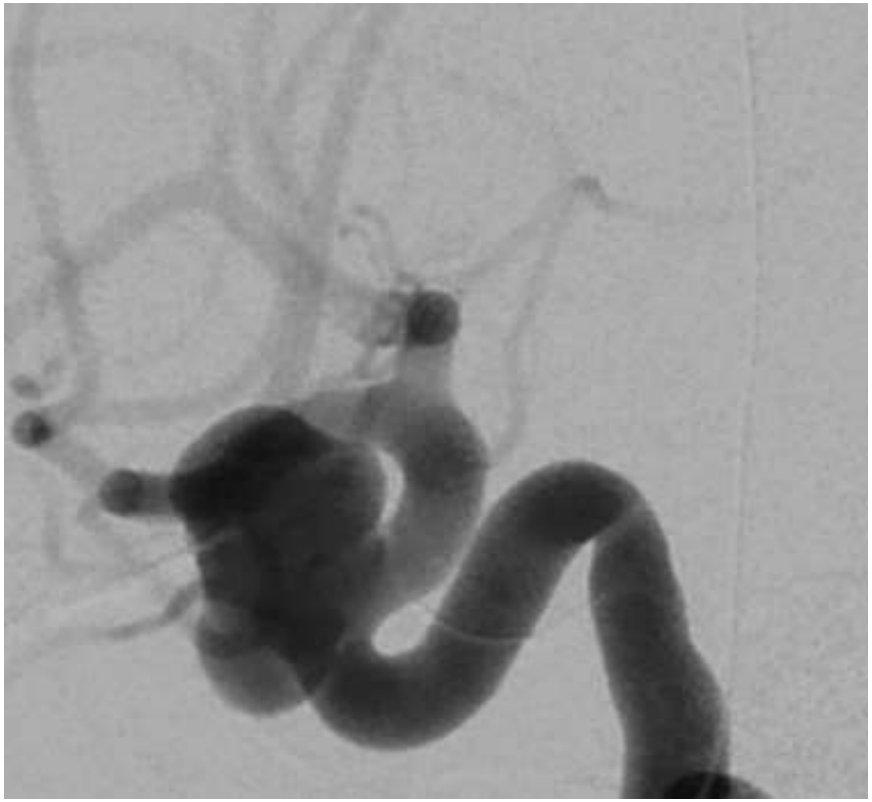

65 y/o F intractable HA

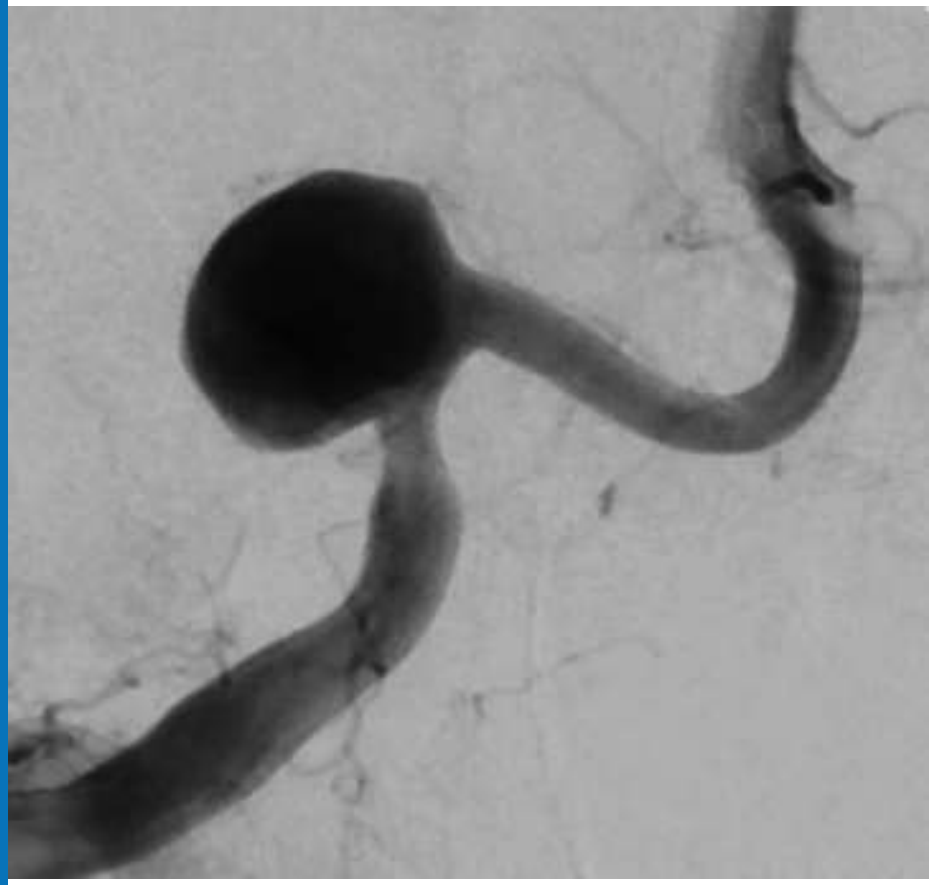

Endoluminal flow diversion for intracranial aneurysms

- High rates of *complete aneurysm occlusion*
- *Durable* form of endovascular treatment
- Dual antiplatelet therapy can limit use
- Complications *not insignificant*, but comparable to other treatment modalities and severity of disease
- Powerful tool for complex aneurysms, selective indications

“Hybrid” stent technology



4.5 x 23 mm LVIS®
Device

3.5 x 23 mm LVIS®
Jr. Device



4.5 x 28 mm
Enterprise™ Stent

3.5 x 30 mm
NeuroForm™
EZ Stent

Braid Pattern Change

LVIS® Rev. C device

LVIS® Blue device



Larger Angle



Smaller Angle

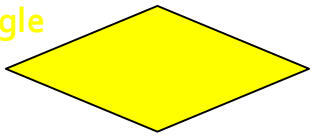

Visible and shapeable

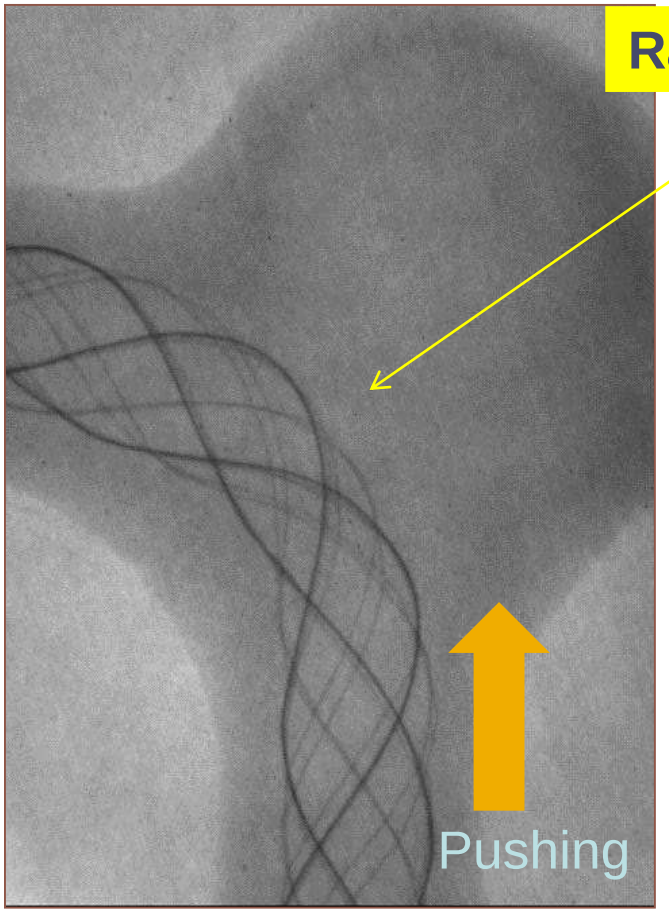

Radiopaque strands

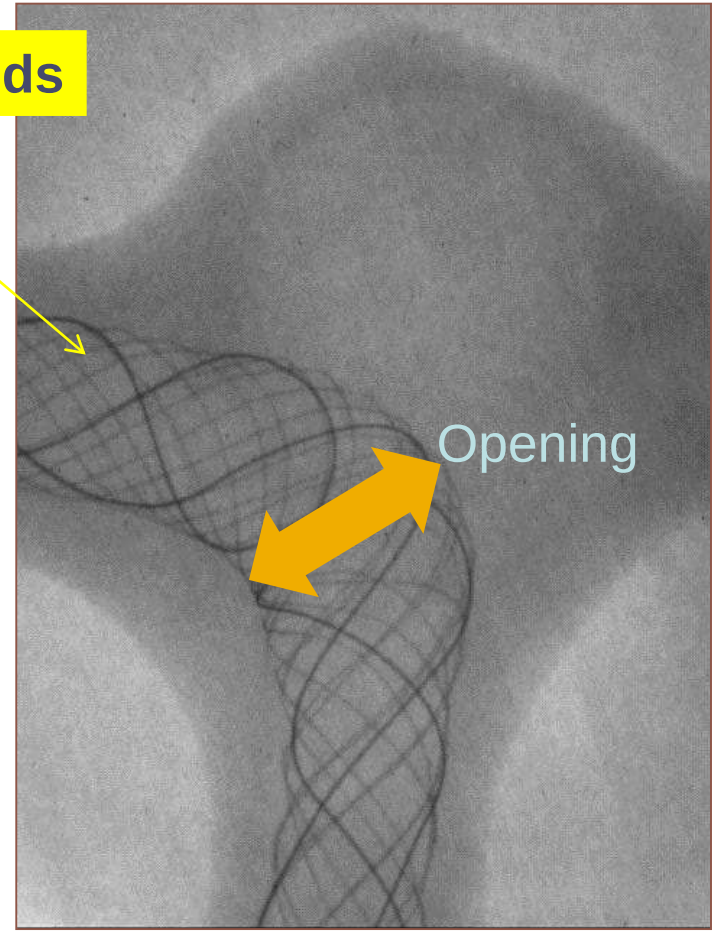

Ruptured L Carotid aneurysm

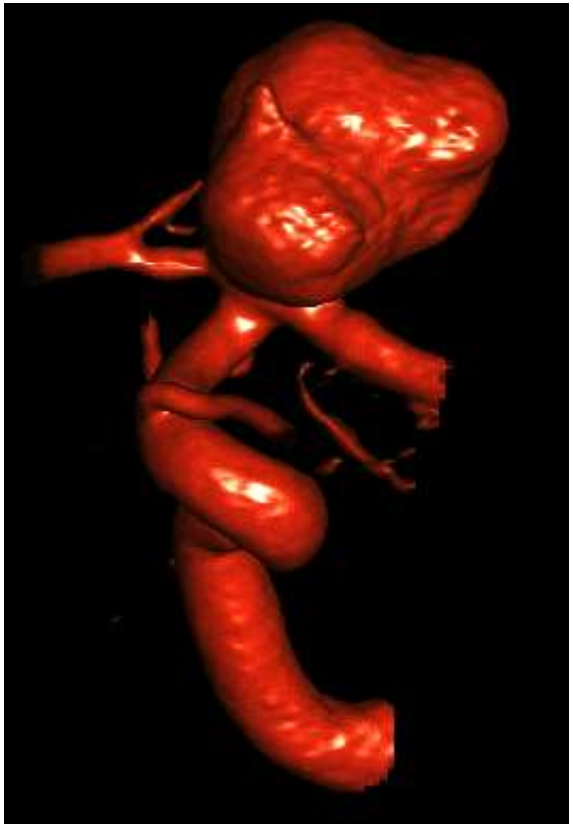

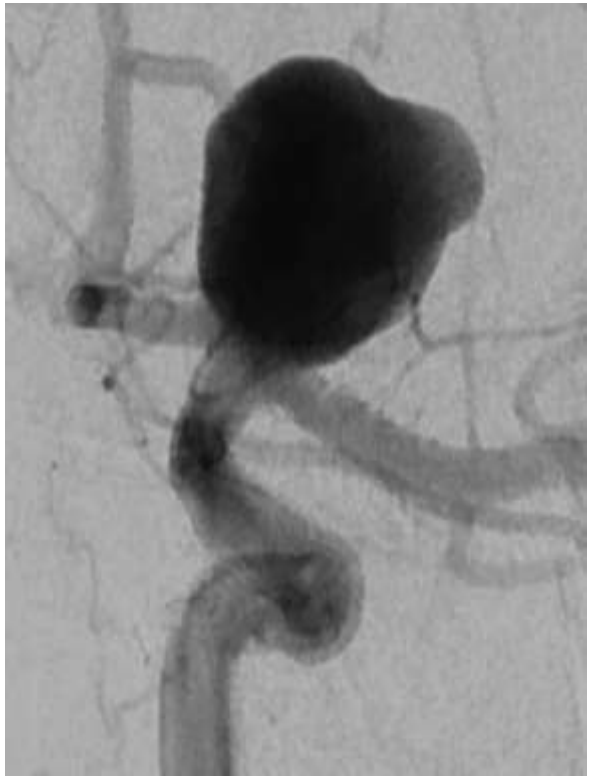

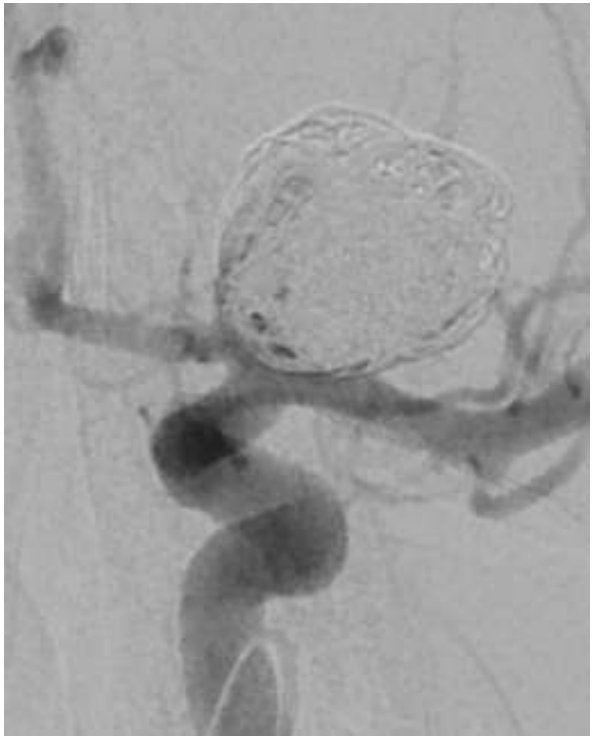

Recurrence, Stent-coil LVIS Blue

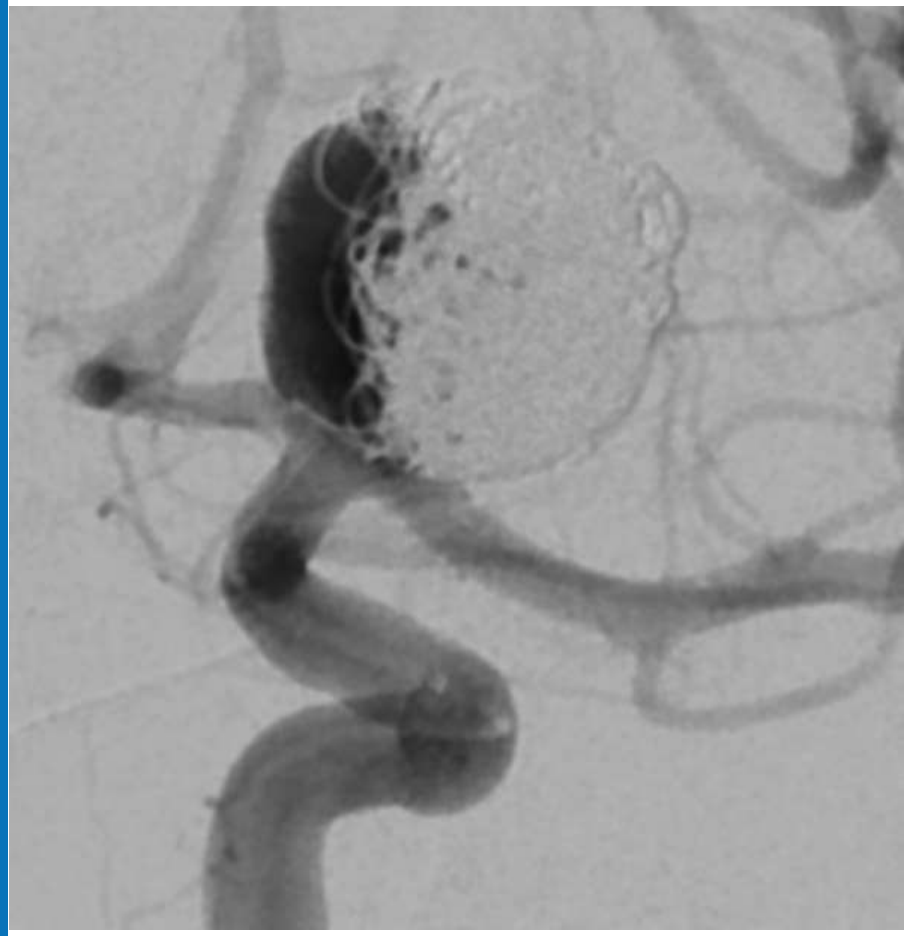

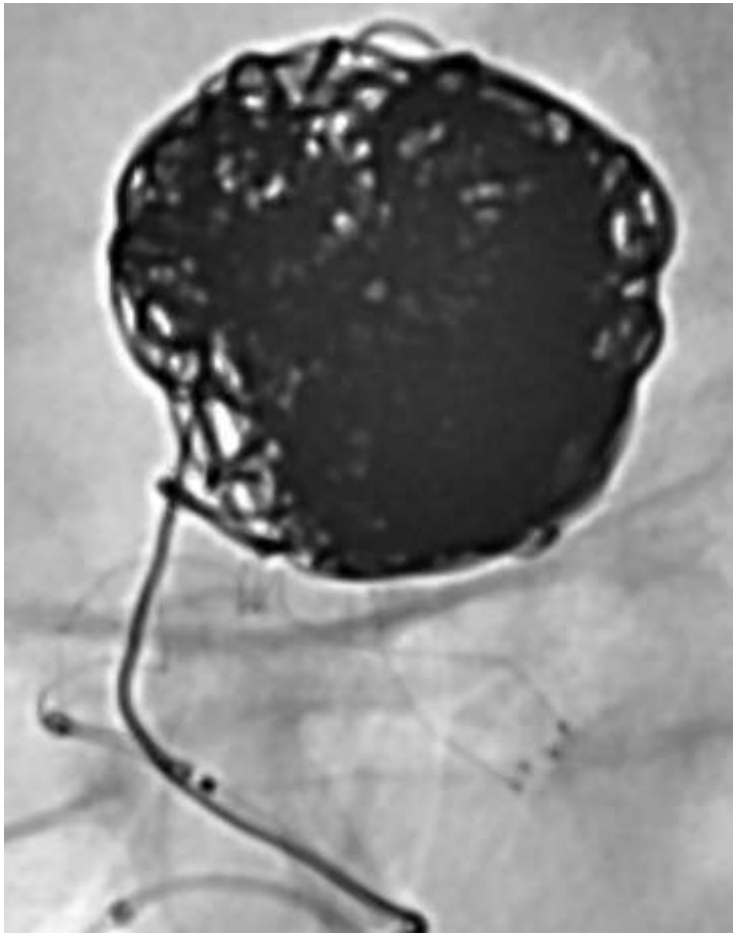

Recurrence, Stent-coil LVIS Blue

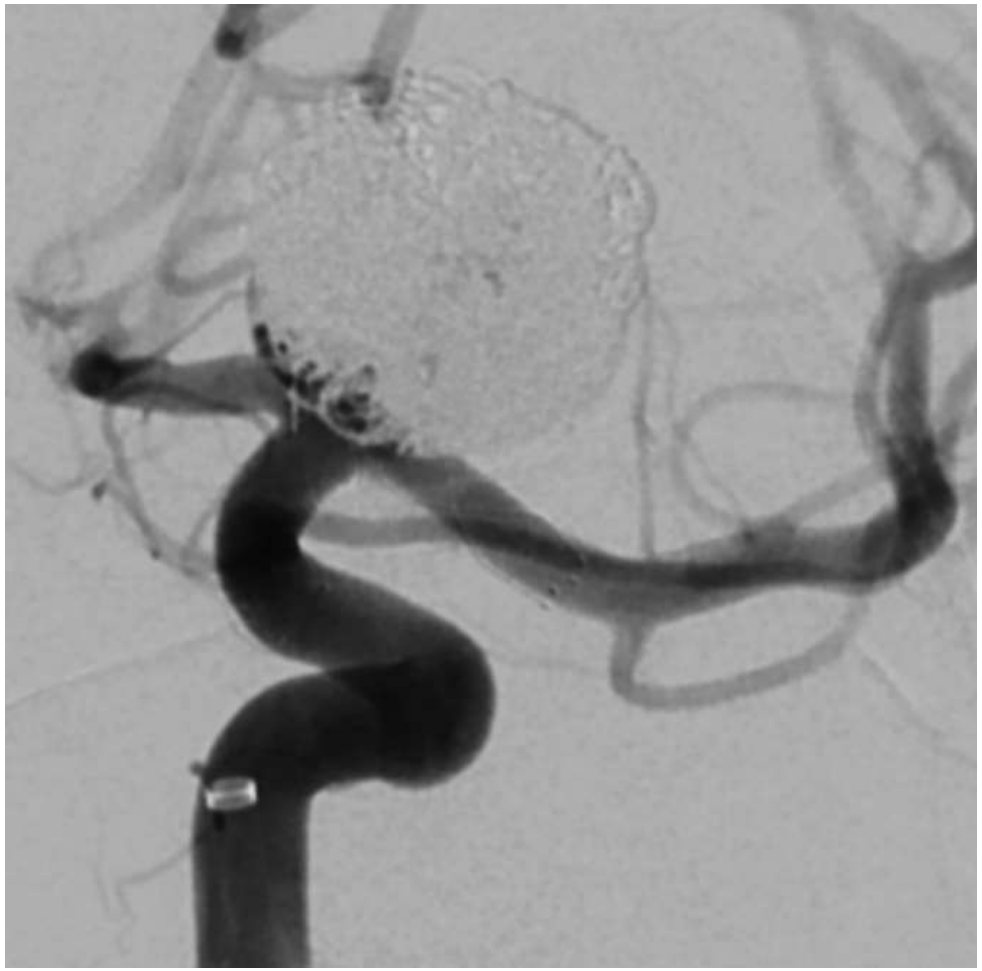

Future Directions

Barrel Stent (Medtronic)

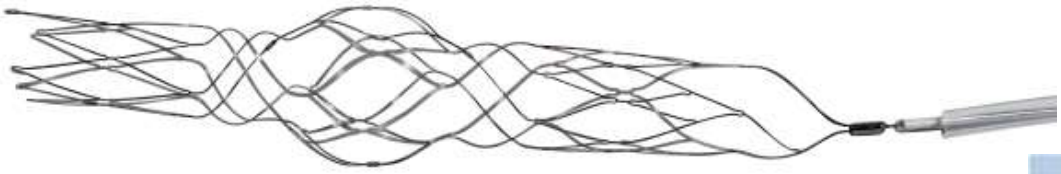


A

Intrasaccular flow disruption

- WEB intrasaccular flow diversion for treatment of ***aneurysm neck*** without compromise of parent artery lumen
- Useful for bifurcation lesions, forego antiplatelet therapy



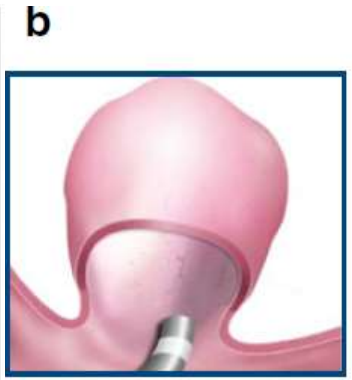

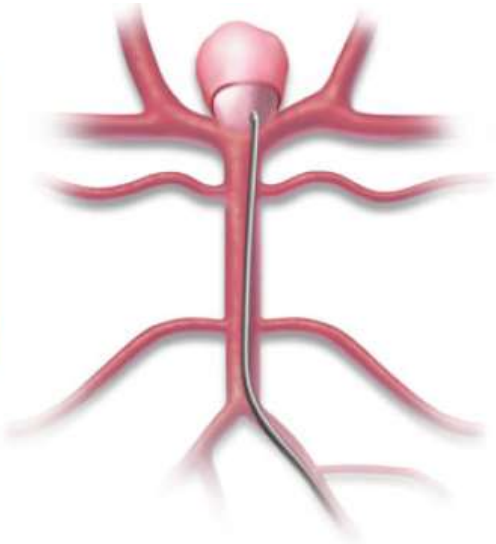

The Woven EndoBridge cerebral aneurysm embolization device (WEB II): initial clinical experience. Klisch J, Sychra V, Strasilla C, Liebig T, Fiorella D. *Neuroradiology*. 2011 Aug;53(8):599-607.

Intrasaccular flow disruption

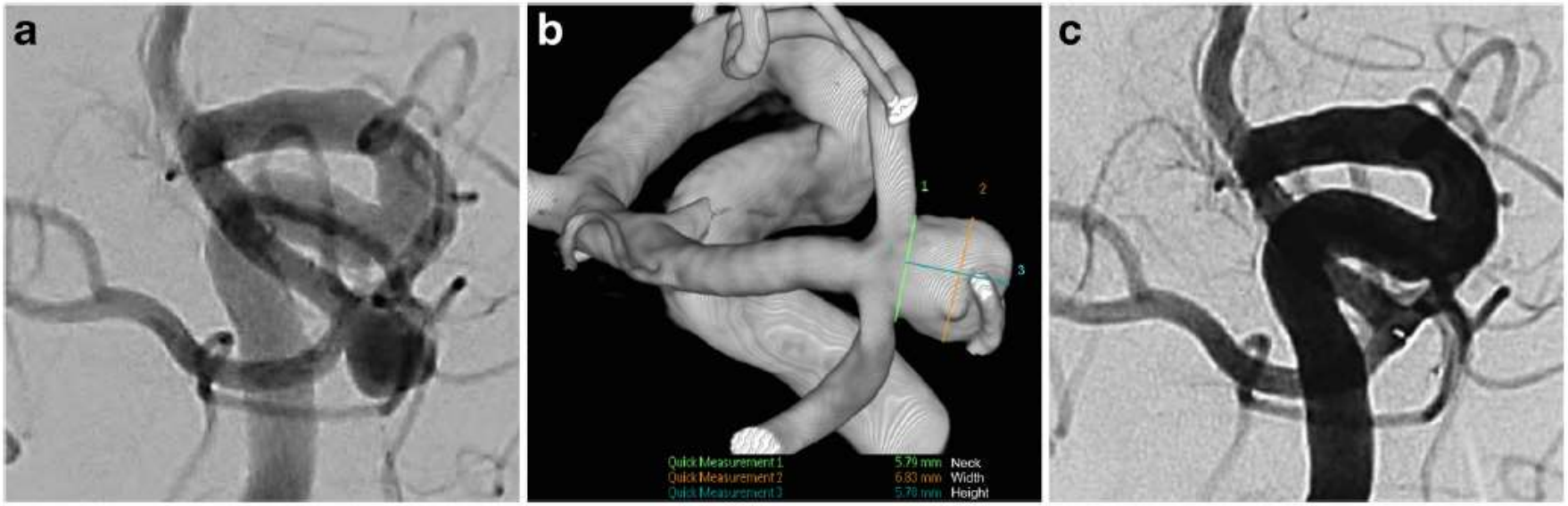

Woven Endobridge (WEB) device for endovascular treatment of ruptured intracranial wide-neck aneurysms: a single-center experience. Caroff J, Mihalea C, Dargento F, Neki H, Ikka L, Benachour N, Moret J, Spelle L. *Neuroradiology*. 2014 Sep;56(9):755-61.

Woven EndoBridge Intrasaccular Flow Disrupter for the Treatment of Ruptured and Unruptured Wide-Neck Cerebral Aneurysms: Report of 55 Cases

D. Behme, A. Berlis, and W. Weber

- 52 patients/55 aneurysms, 14 ruptured
- 51/55 treated with WEB device (93%)
- 6/51 (12%) complications, 1/51 rupture, 0/51 M/M
- At 3 months: 34% occluded, 32% residual neck, 34% residual aneurysm (requiring re-treatment)

What goes wrong when stenting?

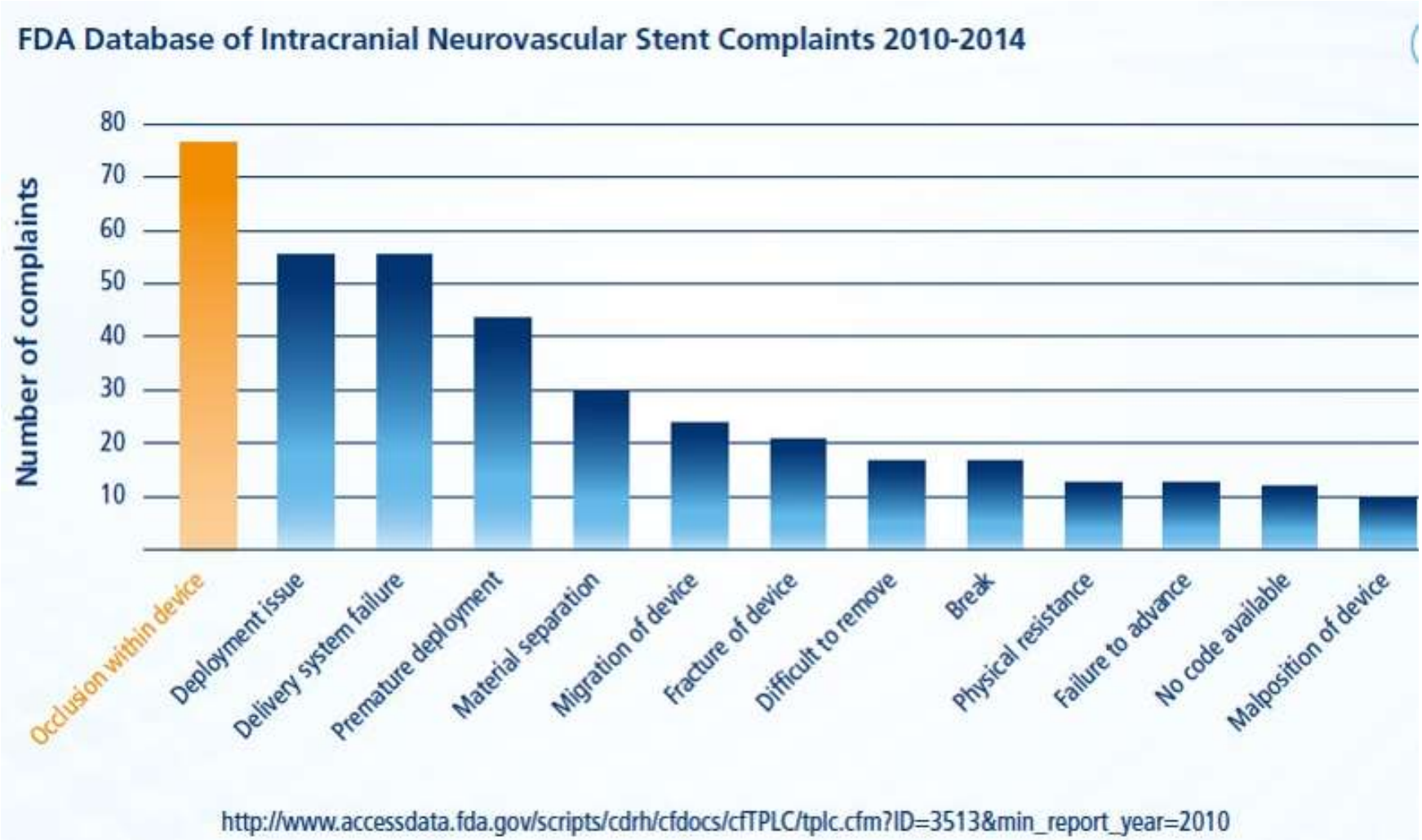

Pipeline Shield Technology (bound synthetic phosphorylcholine)

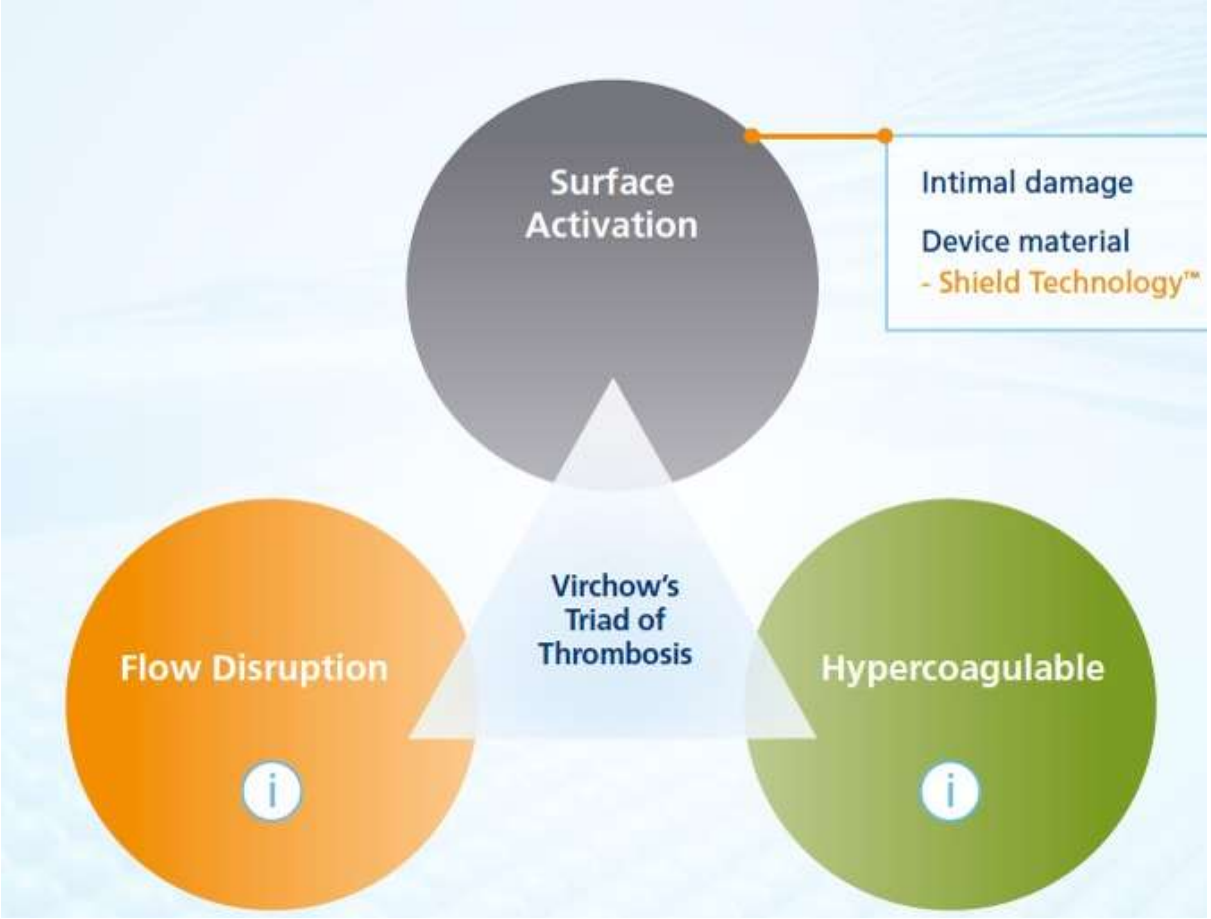

EM of coated device (+3 nm)



In vitro assays of thrombogenicity

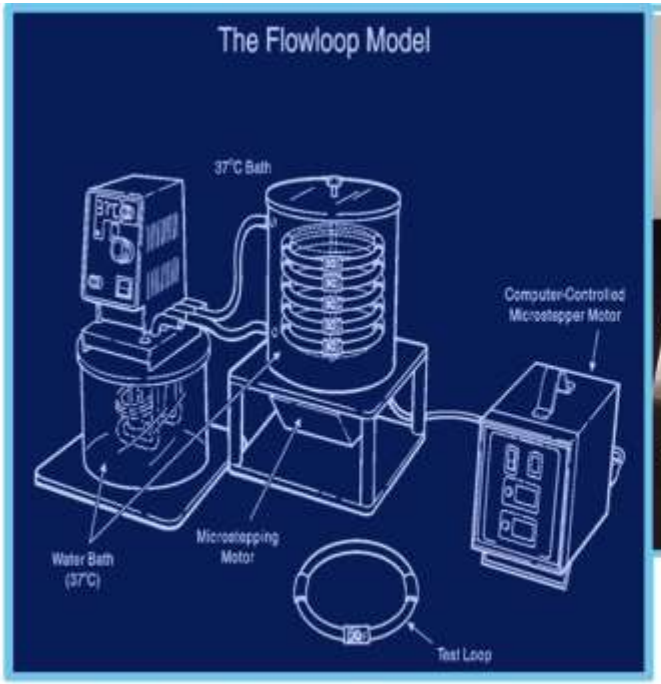





J. Biomater. Sci. Polymer Edn, Vol. 11, No. 11, pp. 1147–1163 (2000)

In vitro assays of thrombogenicity

In vitro assays of thrombogenicity

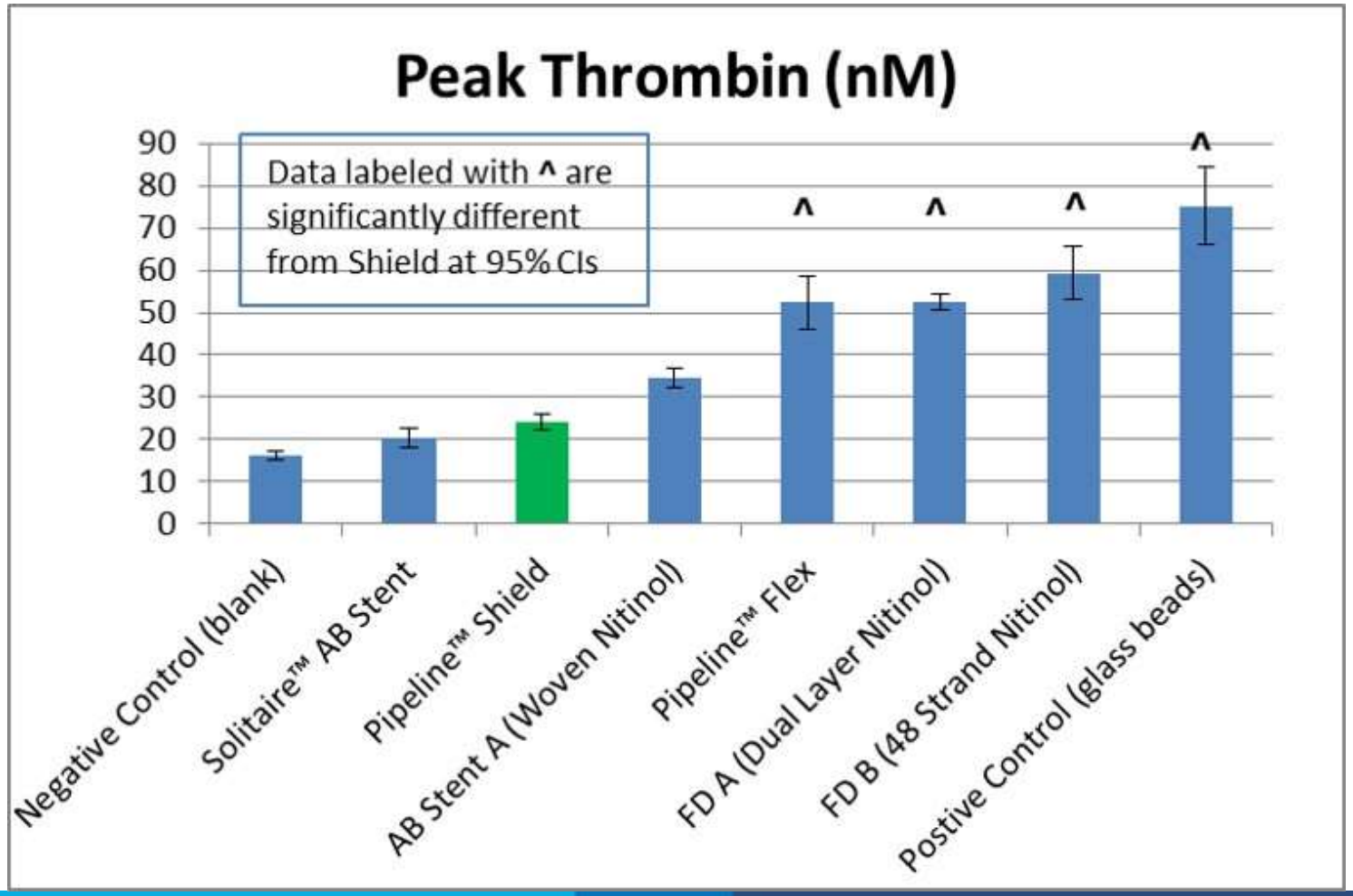

Medina Coil



Future Directions

- Rapidly advancing technology, decreasing technical complications
- Bifurcation lesions, posterior circulation, intrasaccular diversion
- More antiplatelet options/flexibility
- Better outcomes for hemorrhagic cerebrovascular disease!